

# expert


EXcellence in PCOS & Expertise  
in Reproductive Technology



## MODULE 5: MALE INFERTILITY

Brought to you by

THE  
**PCOS**  
SOCIETY  
An Initiative of PCOS Society (India)



**Duru Shah**  
Founder President,  
The PCOS Society of India,  
Course Director, **EXPERT**



**Madhuri Patil**  
Scientific Co-ordinator,  
The PCOS Society of India,  
Course Director, **EXPERT**

PCOS is quite often associated with infertility, especially in women with irregular periods and hyperandrogenemia. It is one of the most treatable forms of infertility, if ovulation induction is optimal. Unfortunately, many PCOS women, both lean and obese, behave erratically during ovulation induction sometimes leading to ovarian hyperstimulation syndrome which can become a serious iatrogenic complication. Keeping in mind that many PCOS women approach us for management for their infertility issues, it is important for us to understand the principles of management. Which when applied correctly, they can give us great success in making PCOS women pregnant. Of course experience counts, and as we continue treating women, we learn how to tweak our stimulation protocols to avoid complications and give us the best results!

After initiating the Basic Course on Infertility in 2018, we are delighted to introduce to you the Advanced Course called **“EXPERT” - (Excellence in PCOS and Expertise in Reproductive Technology)** a Certificate Course brought to you by the PCOS Society of India, through an unrestricted educational grant by Sun Pharma, Inca Life Sciences.

**“EXPERT”** will be presented to you in a set of 6 Modules which will update you on various aspects of the management. Infertility in PCOS, from minimal intervention to Assisted Reproduction.

Once you complete the 6 Modules, you could participate in an Online Exam, Assessment and on clearing it, you will be eligible to receive a beautiful certificate from the PCOS Society of India, which you will be extremely proud to display! To own this Certificate, you need to be a member of the PCOS Society, India!

To become a member, please log on to <http://www.pcosindia.org/> to download your form and become a Life Member or Patron Member of the PCOS Society of India

If you have any queries, please write to us at [thepcossociety@gmail.com](mailto:thepcossociety@gmail.com)

Both Madhuri and myself have worked hard on creating this program and we thank the team at Sun Pharma for their support in making this program a reality!

Enjoy reading.

With warm regards,

**Duru Shah**  
Founder President, The PCOS Society of India.  
Course Director, **EXPERT**

**Madhuri Patil**  
Scientific Co-ordinator, The PCOS Society of India  
Course Director, **EXPERT**

**MALE INFERTILITY**

<b>Male Infertility: An Overview</b> .....	1
• Introduction .....	1
• Epidemiology and Distribution .....	1
• Trends in Male Infertility .....	1
• Role of Spermatozoa .....	1
• Etiology and Classification of Male Infertility .....	2
• Prognostic Factors .....	2
• Summary .....	2
<b>Components of Complete Evaluation for Male Infertility</b> .....	3
• Goals of Evaluation .....	3
• Indications for Evaluation .....	3
• History-Taking and Physical Examination .....	3
• Summary .....	4
<b>Semen Analysis</b> .....	4
• Collection of Sample .....	4
• What to Look for in Semen Analysis, to Determine the Pathology? .....	4
• Determination of Sperm Count .....	4
• Determination of Sperm Vitality .....	4
• Assessment of Sperm Morphology .....	5
♦ Counting of Cells Other Than Spermatozoa .....	5
♦ Agglutination .....	5
• Testing for Presence of Anti-sperm Antibodies .....	5
• Assessment of Semen Biochemistry .....	5
♦ WHO 5 Manual (2010)–What is Objectionable? .....	6
♦ Recommendations From ESHRE .....	6
• Summary .....	6
<b>Importance of Sperm Function Testing in Diagnosis of Male Infertility</b> .....	6
• Post-coital Test (PCT) .....	6
• Clinical Implications of Hypo-osmotic Swelling Test .....	7
• Clinical Implications of Teratozoospermia Index .....	7
• Computer-Assisted Sperm Analysis: Advantages and Disadvantages .....	7
• Is Production of Reactive Oxygen Species a Cause of Concern? Good and Bad Sides .....	7
• Laboratory Signs Suggesting Possible Sperm Oxidative Stress .....	8
• Measurement of Reactive Oxygen Species in Human Semen .....	8
• Reactive Oxygen Species: Why is it not a Mainstream Investigation in the Evaluation of Male Infertility? .....	8
• Evaluation of Sperm DNA Fragmentation .....	8
• Evidence Linking Sperm DNA Fragmentation to Poor Reproductive Outcomes .....	9
• Correlation Between Sperm DNA Damage and Pregnancy .....	9
• Indications for Sperm DNA Testing .....	9
♦ Acrosome Reaction .....	9
• Clinical Implications of Acrosin Activity Test .....	10
• Biochemical Tests: Creatine Kinase .....	10
♦ Clinical Utility .....	10
• Sperm Penetration and Sperm Binding Tests .....	10
• Does the Sperm Function Test Improve the Efficacy of Diagnosis and Treatment? Should it be Done in All Sub-fertility Cases? .....	11
• Summary .....	11

<b>Extended Screening in Male Sub-fertility</b> .....	11
• Reproductive and Sexual History .....	11
• Physical Examination and Ultrasound .....	11
• Ultrasonography .....	12
♦ Scrotal Ultrasonography .....	12
• Endocrine Evaluation .....	12
• Post-ejaculatory Urinalysis .....	12
• Genetic Screening .....	12
♦ Sperm Chromosome Aneuploidy .....	13
♦ Testicular Biopsy .....	13
• Predictor for Sperm Recovery .....	14
<b>Management of Male Infertility</b> .....	14
• Medical Management .....	14
♦ Treatment for Increased DFI .....	15
♦ Surgical Therapy .....	15
• Treatment of Azoospermia .....	15
• Summary .....	16
• Indications for Assisted Reproduction .....	16
<b>Algorithms for Male Factor Evaluation</b> .....	17
<b>References</b> .....	19

# MALE INFERTILITY

## Male Infertility: An Overview

### Introduction

Infertility is associated with a psychological burden, and affects couples globally.<sup>1,2</sup> According to World Health Organization, 'infertility is the ability of a sexually active, non-contracepting couple to achieve spontaneous pregnancy in one year.'<sup>2</sup> Male infertility is defined as the inability of a man to impregnate a fertile woman.<sup>2</sup>

### Epidemiology and Distribution

Overall, about 15% of the world population is infertile.<sup>1</sup> Approximately 20% of infertility in couples arises due to the male factor.<sup>3</sup> Male-infertility-associated factors, along with abnormal semen parameters, are found in almost 50% of infertile couples.<sup>4</sup>

Data from a meta-analysis reveal that male infertility ranges from 2.5% to 12% globally. Figure 1 shows the rates of infertility cases associated with the male factor in various regions.<sup>1</sup>

### Trends in Male Infertility

Many clinicians and scientists have reported concerns regarding deteriorating semen quality since the 1980s. A meta-analysis conducted to provide evidence on the concerns mentioned reported a decline in the

sperm count of healthy men by 1% per year between 1938 and 1990. Also, a statistically significant, 50% reduction in the mean sperm count from  $113 \times 10^6 \text{ mL}^{-1}$  in 1940 to  $66 \times 10^6 \text{ mL}^{-1}$  in 1990 and seminal volume from 3.40 to 2.75 mL was reported.<sup>2</sup>

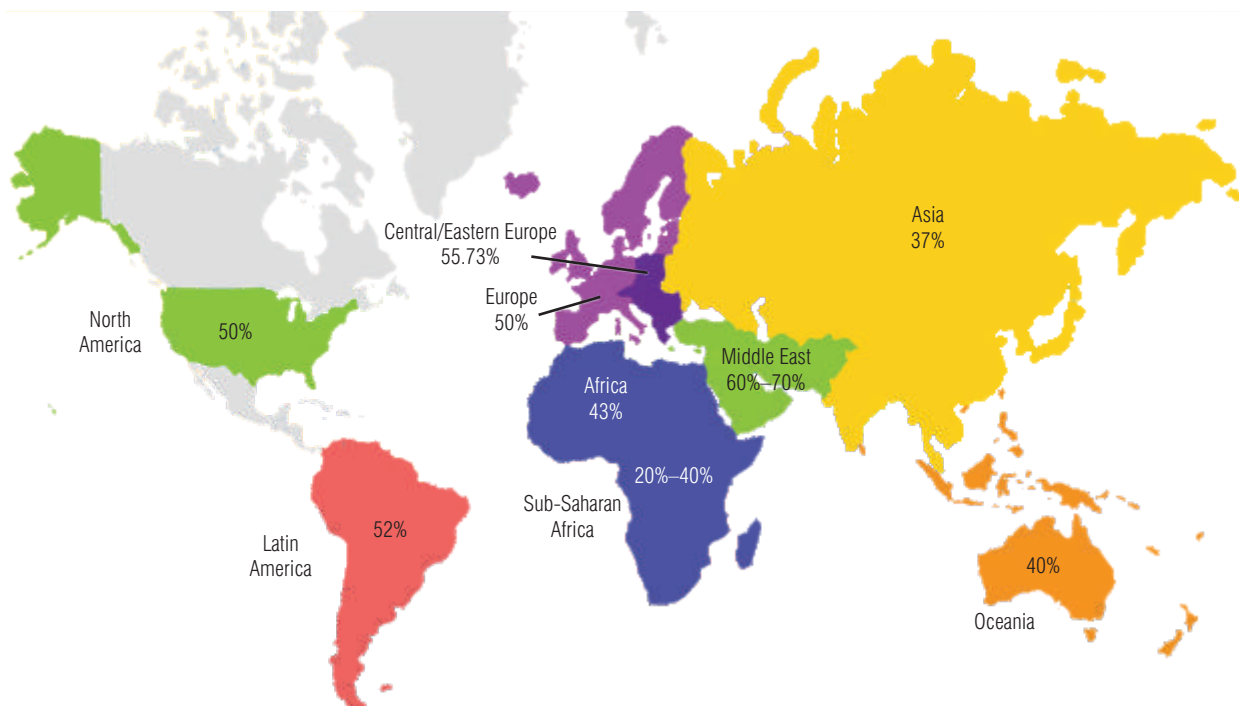
A meta-analysis conducted in 2000 confirmed a declining trend in sperm count, and another meta-analysis reported a decrease in sperm density by about 50% worldwide. Studies conducted between 1995 and 2007 revealed a declining trend in semen quality, seminal volume, sperm count, motility, viability, normal morphology—as well as a reduction in alpha-glucosidase and fructose levels in relation to age.<sup>2</sup> However, many studies showed no change in seminal parameters over time. These studies confirmed that there is no relation between the quality of semen parameters and their deterioration over time.<sup>2</sup>

### Role of Spermatozoa

The primary role of spermatozoa in fertilization is to contribute a haploid set of chromosomes with paternal pattern of gene imprinting. Spermatozoa also triggers oocyte activation via cortical granule exocytosis, causes meiosis resumption and completion with spindle formation and subsequently initiate metabolic events required to support embryonic development, epigenetic and structural inheritance (centrosome).<sup>5</sup>

The natural process of fertility involves the fusion of the spermatozoon with the oocyte and requires both gametes to be structurally normal, viable, and functionally competent.<sup>5</sup>

**Figure 1: World map containing percentages of infertility cases per region due to the male factor.<sup>1</sup>**



Sperm characteristic important for fertilization:

- Normal morphology
- Normal intact acrosome
- Straight line velocity (VSL) and linearity (LIN)
- Ability to bind to zona pellucida
- Ability to penetrate the zona pellucida
- Ability to fuse with the oolemma
- Activate the oocyte
- Ability to form pronucleus<sup>5</sup>

## Etiology and Classification of Male Infertility

The cause for male sub-fertility remains frequently obscure in about 30% of cases (idiopathic infertility). In another 25%, chromosomal abnormalities and mutations (Klinefelter's syndrome [47, XXY], chromosomal aberrations, cystic fibrosis [CF], congenital bilateral absence of vas deferens, or Y-chromosomal AZF deletions) are responsible. In the remaining, fertility impairment may be due to maldescended testis, infections, varicocele, idiopathic testicular tumors, lymphomas, leukemia, sarcoma, secondary hypogonadism, obstructions, and vasectomy (Table 1).<sup>5</sup>

The exact reason for male infertility cannot be determined in most men being treated for infertility.<sup>5</sup>

	<b>Etiology</b>	<b>Frequency</b>
1	Primary testicular disorders a. Klinefelter's syndrome and variants b. Cryptorchidism c. Orchitis d. Irradiation e. Cytotoxic therapy f. Partial androgen resistance	10%–13%
2	Hypothalamo-pituitary disease Idiopathic, tumors, hyperprolactinemia	1%
3	Genital tract obstruction Congenital or acquired obstruction of vas deferens or epididymis	8%–10%
4	Previous vasectomy	–
5	Sperm autoimmunity	4%–6%
6	Drugs, toxins, stress, illness Environmental exposure to pseudo or xenoestrogens and antiandrogens	–
7	Lifestyle–Smoking, occupation, dressing habits Less consumption of omega-3 fatty acids, time spent in commuting	–
8	Coital problems	1%
9	Idiopathic	70%–75%
10	Poor sperm motility, teratozoospermia, varicocele, chronic prostatitis	–

Male infertility can also be classified based on the effectiveness of the treatment (Table 2).<sup>5</sup> The effectiveness of treatment may be defined as 'medical intervention known or proved by clinical trial to improve the chances of the man producing a conception by coitus or artificial insemination and does not include the use of *in vitro* fertilization or intracytoplasmic sperm injection to bypass the impairment.'<sup>5</sup>

<b>Type of infertility</b>	<b>Frequency (%)</b>
<b>Untreatable sterility</b>	12%
Primary seminiferous tubule failure	12%
<b>Treatable conditions</b>	18%
Sperm autoimmunity	7%
Obstructive azoospermia	10%
Gonadotropin deficiency	0.5%
Disorders of sexual function	0.5%
Reversible toxin effects	0.02%
<b>Untreatable subfertility</b>	70%
Oligospermia	35%
Asthenozoospermia and teratozoospermia	30%
Normospermia with functional defects	5%

## Prognostic Factors

Prognostic factors for male infertility are:

- Duration of infertility
- Primary or secondary infertility
- Results of semen analysis
- Age and fertility status of female partner<sup>4</sup>

## Summary

- Male infertility is defined as the inability of a man to impregnate a fertile woman.
- Overall, about 15% of the world population is infertile and approximately 20% of infertility in couples arises due to the male factor.
- Various studies confirm that there is no relation between the quality of semen parameters and their deterioration over time.
- The key etiological or contributory factors that may lead to reduced male fertility include: congenital or acquired urogenital abnormalities, malignancies, urogenital tract infections, increased scrotal temperature (e.g. as a consequence of varicocele), endocrine disturbances, genetic abnormalities, and immunological factors.

## Components of Complete Evaluation for Male Infertility

### Goals of Evaluation

The goals of evaluation should include identification and treatment of conditions that can improve the fertility of the male under evaluation, to allow conception naturally. Evaluation of an infertile male also helps in detecting any underlying medical conditions related to infertility. Any genetic causes of infertility, if detected, should be informed to the patient. The risk of transmitting genetic abnormalities to the offspring and the available treatment options should be discussed with couples.<sup>3</sup>

### Indications for Evaluation

Couples who are unable to conceive even after 12 months or more of regular unprotected intercourse, require evaluation for infertility. At times earlier evaluation may be justified, based on medical history and physical findings, and is warranted after 6 months for couples in which the female partner is over age 35 years. The initial screening of the male partner with a concern of infertility should include a reproductive history and semen analysis. If the initial evaluation of the semen is abnormal, then a repeat semen analysis is done one month apart. A second abnormal test should prompt a complete evaluation by a specialist in male reproduction.<sup>3</sup> Depending on the semen analysis, further investigations are done, including complete evaluation of the male partner, hormonal assay, ultrasound examination of the scrotum, karyotyping and molecular genetics, examination of post-ejaculatory urine sample, sperm function test, and testicular biopsy.<sup>3</sup>

### History-Taking and Physical Examination

A detailed history should be obtained, to identify factors leading to infertility. The important aspects of history-taking for an infertile male are listed below (Table 3).<sup>6</sup>

A physical examination is an important part of the initial evaluation of infertile men; it involves:

- General examination to identify:
  1. Incomplete masculinization
  2. Presence or absence of clinical features associated with hypothalamic or pituitary defects
  3. Palpation of thyroid
  4. Auscultation of heart and lungs—Rule out chronic bronchitis
  5. Situs inversus with immotile sperms—Kartagener's syndrome
  6. Gynecomastia—Estrogen-secreting testicular neoplasms, adrenal tumors, and liver disease
  7. Nipple discharge—Prolactin-secreting pituitary adenoma
  8. Palpation of abdomen for hepatic dysfunction, which may be associated with altered sex steroid metabolism<sup>3</sup>

**Table 3: Clinical male infertility history outline<sup>6</sup>**

#### Infertility history

- Age of partners, time attempting to conceive
- Contraceptive methods/duration
- Previous pregnancy (actual partner/other partner)
- Previous treatments
- Treatments/evaluation of female partner

#### Sexual history

- Potency, libido, lubricant use
- Ejaculation, timed intercourse, frequency of masturbation

#### Childhood and development

- Cryptorchidism, hernia, testicular trauma
- Testicular torsion, infection (e.g., mumps)
- Sexual development, puberty onset

#### Personal history

- Systemic diseases (diabetes, cirrhosis, hypertension)
- Sexually transmitted diseases, tuberculosis, viral infections

#### Previous surgeries

- Orchiopexy, herniorrhaphy, orchiectomy (testicular cancer, torsion)
- Retroperitoneal and pelvic surgery
- Other inguinal, scrotal, and perineal surgery
- Bariatric surgery, bladder neck surgery, transurethral resection of the prostate

#### Gonadotoxin exposure

- Pesticides, alcohol, cocaine, marijuana abuse
- Medication (chemotherapy agents, cimetidine, sulfasalazine, nitrofurantoin, allopurinol, colchicine, thiazide,  $\beta$ - and  $\alpha$ -blockers, calcium blockers, finasteride)
- Organic solvents, heavy metals
- Anabolic steroids, tobacco use
- High temperatures, electromagnetic energy
- Radiation (therapeutic, nuclear power plant workers), etc.

#### Family history

- Cystic fibrosis, endocrine diseases
- Infertility in the family

#### Current health status

- Respiratory infection, anosmia, galactorrhea, visual disturbances, obesity

- Genital examination to identify:
  1. Examination of penis and urethra for congenital or acquired abnormalities—Hypospadias, infection
  2. Testicular size and consistency
  3. Any induration, nodularity, or irregularity of epididymis
  4. Palpation of vas deferens
  5. Presence of hydrocele or varicocele
  6. Rectal examination for prostate and seminal vesicles<sup>3</sup>

The diagnosis of congenital bilateral aplasia of the vasa deferentia (CBAVD) is established by a physical examination.<sup>3</sup>

## Summary

- The goals of evaluation should include identification and treatment of conditions that can improve the fertility of a male under evaluation, to allow conception naturally.
- Couples who are unable to conceive even after 12 months or more of regular unprotected intercourse, require evaluation for infertility.
- Abnormal results on the initial evaluation should prompt a complete evaluation by a specialist in male reproduction.
- History-taking and physical examination are important aspects of the basic examination.
- Semen analysis, endocrine evaluation, post-ejaculatory urinalysis, ultrasonography, and specialized tests on semen and sperm are the basic investigations used in the evaluation of male infertility.

## Semen Analysis

### Collection of Sample

The sample for semen analysis can be collected in a specimen collection bottle made of polypropylene or in special semen-collecting condoms. Ideally, the specimen should be collected in the premises of the laboratory in specially designated semen collection rooms and not the toilet.<sup>3,7</sup> If a patient wishes to collect a sample at home, the sample of semen should be brought to the lab within 30–60 minutes of collection and maintained at room or body temperature. If the sample is collected at home, the patient's signature should be taken on a special consent form that mentions that the sample has been brought from home. This is important for medicolegal purposes.<sup>7</sup>

### What to Look for in Semen Analysis, to Determine the Pathology?

The semen analysis provides information on semen volume, pH, liquefaction, viscosity, sperm concentration, motility, viability, morphology and agglutination. Whereas, sperm function test evaluates semen cytology and biochemistry.<sup>3</sup>

The table below lists the lower limits of the accepted reference values for semen analysis (Table 4).<sup>3</sup>

If the semen analysis is normal, we could do a sperm function test to distinguish between sperm dysfunction and unexplained infertility.<sup>3</sup>

### Determination of Sperm Count

Sperm count an important part of semen analysis.<sup>7</sup> Patients with abnormal results in at least two tests require further evaluation. Sperm numbers also help in identifying the following:<sup>4</sup>

- **Oligozoospermia:** Sperm count <15 million/mL
- **Asthenozoospermia:** Progressive motility <32%
- **Teratozoospermia:** <4% of normal sperm forms
- **Azoospermia:** Absence of sperms in the ejaculate<sup>4</sup>

**Table 4: Lower limits of accepted reference values for semen analysis<sup>3</sup>**

#### WHO (2010) Reference Values

- Volume—At least 1.5 mL or greater
- pH—7.2 or more
- Presence of fructose
- Sperm concentration—15 million/mL
- Total sperm number—39 million spermatozoa per ejaculate or more
- Total motility (PR+NP)—40%
- Progressive motility—32%
- Vitality—58% or more live
- Morphology—4% more normal forms (14% strict Kruger criteria)
- White blood cells—Fewer than 1 million/mL
- Round cells—Fewer than 5 million/mL
- Immunobead test—<50%
- MAR test—<50% motile spermatozoa with adherent particles

#### Interpretation of semen analysis

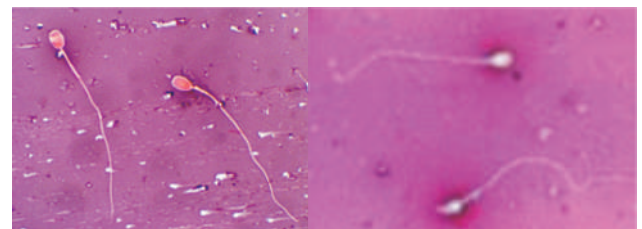
Abnormalities that can be present in semen

- Volume—Low or high
- Viscosity—Normal, hyperviscous
- Absence of fructose
- Count—Absent, low, normal
- Motility—Normal, low, absent
- Morphology—High TZI
- Agglutination—Antisperm antibody
- Infection<sup>3</sup>

### Determination of Sperm Vitality

Sperm vitality is a measure of 'live' sperms; it can be measured by assessing the ability of the plasma membrane of the sperm to exude extra-cellular substances such as dyes.<sup>8</sup> Sperm vitality can be assessed using the eosin-nigrosin test and the hypo-osmotic swelling (HOS) test. The eosin-nigrosin test gives a clear picture of both positively and negatively stained spermatozoa.<sup>7</sup> Spermatozoa that are stained pink or red are counted as dead, whereas the unstained (white) ones are counted as live (Figure 2). The sample stained with this dye cannot be used for any further procedures.<sup>8</sup>

**Figure 2: Pink stained spermatozoa are nonviable sperms as compared to white ones with intact membranes.<sup>8</sup>**

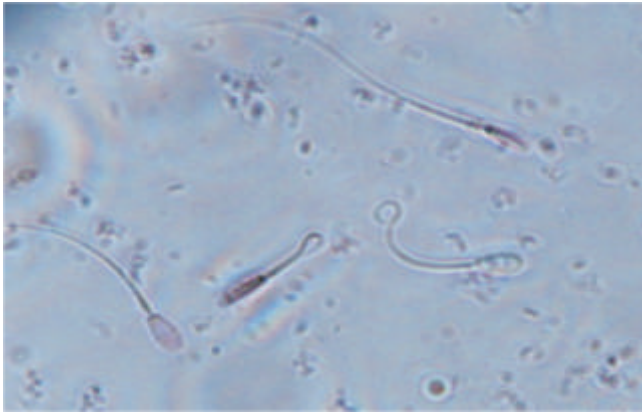


Another important procedure used to determine sperm vitality is the hypo-osmotic swelling (HOS) test. The HOS test gives information on the membrane integrity of sperm. A good correlation exist between positive HOS reaction and fertilization rate in an IVF procedure. According to WHO 2010, at least 50% of the sperms produced should be positive to HOS test.<sup>9</sup>

- Normal—> 50 %: Patients benefit with IUI
- Borderline—40%–50%: Gray zone and may be subjected to IVF if the post wash count is at least 10 million/mL
- Abnormal—< 40 %: Benefit by ICSI<sup>9</sup>



**Figure 3: Hypo-osmotic swelling test.<sup>9</sup>**



This test not only helps in detecting vitality, but can also be used for selection of sperms for intracytoplasmic sperm injection (ICSI) in cases where all sperms are immotile, (necrozoospermia) though live.<sup>9</sup>

### Assessment of Sperm Morphology

According to WHO (2010) criteria, normal sperm morphology greater than 4% is considered to be normal, whereas according to Kruger's criteria, it is greater than 14%. According to the classification system evolved by Kruger *et al.*, and based on the criteria accepted by WHO, normal spermatozoa have the following attributes:<sup>8</sup>

- The head of a normal sperm should be 3–5  $\mu$  in length and 2–3  $\mu$  in width, with a perfect oval shape.
- The mid-piece of the sperm should be about 1  $\mu$  in diameter with a straight and regular outline and aligned to the longitudinal axis of the head, and should be 7–8  $\mu$  long.
- The tail of the sperm must be slender, uncoiled, and at least 45  $\mu$  long.<sup>8</sup>

Sperm morphology is evaluated by preparing a semen smear and staining it with either Shorr or Papanicolaou stain. Computer-aided sperm morphometric assessment can also be performed.<sup>8</sup>

### Counting of Cells Other than Spermatozoa

Semen cytology: White blood cells—Polymorphs, epithelium cells, histiocytes, and ghost cells (cytoplasm without a nucleus)

- White blood cells evaluated—Fewer than 1 million/mL
- Round cells—Fewer than 5 million/mL<sup>8</sup>

Peroxidase activity or leukocyte markers differentiate WBCs from immature cells. If the levels of peroxidase-positive granulocytes are greater than 106/mL, one should advise a semen culture.<sup>8</sup>

### Agglutination

Agglutination is of two types

- Non-specific agglutination, where sperm adhere to cells present in the seminal plasma<sup>8</sup>
- Specific agglutination, where sperms adhere to each other

Sperm agglutination indirectly indicates the presence of sperm antibodies and is associated with infection (i.e., orchitis), testicular trauma, or when there is history of vasectomy. The incidence is 10% in infertile men (3%–20%) as compared to 2% in fertile men.<sup>8</sup>

### Testing for Presence of Anti-sperm Antibodies

Anti-sperm antibodies are formed in the cervical mucus (Immunoglobulins A [IgA]) of the female or can circulate in the blood and other body fluids (IgG type), due to repeated exposure to sperms. The extent of the effect of these antibodies on the fertility of sperms is unknown, but there are various tests that can be carried out to detect the presence of antibodies, such as:<sup>8</sup>

- Immunobead test
- Mixed antiglobulin reaction (Coombs test)
- Elisa estimation of antibodies<sup>8</sup>

The most common procedures performed to test the presence of anti-sperm antibodies are direct immunobead and mixed antiglobulin reactions. The presence of 50% or more immunobead-reacted or mixed antiglobulin-reacted sperms indicates subfertility.<sup>8</sup>

### Assessment of Semen Biochemistry

The biochemical composition of the seminal plasma is complex. The seminal plasma consists of various substances, some of which are specific to the accessory gland and contribute to a fraction of the ejaculate. The most important secretions are from the seminal vesicles and the prostate gland, with each secretion having a unique marker that helps in detecting the presence, absence, dysfunction, or infection of the specific glands they are secreted from. Common secretions in the male genital tract that help to assess the impairment of epididymal, vesicular, and prostatic function are listed below:<sup>8</sup>

- **Prostate gland:** Acid phosphatase, citric acid, zinc, and magnesium
- **Seminal vesicles:** Fructose and prostaglandins
- **Epididymis:** L-carnitine, alpha-glucosidase, and glycerophosphocholine<sup>8</sup>

The role of these secretions in sperm function is still uncertain. It is presumed that zinc plays a role in protecting and stabilizing condensed sperm chromatin, whereas fructose (which is secreted by the seminal vesicles) acts as an energy source for the spermatozoa, for anaerobic metabolism. Fructose is the major energy source for the sperm, and removal of the seminal vesicular component from the ejaculate will result in immotile sperms. Therefore, fructose acts as a marker for seminal vesicle function and its levels in semen are androgen-dependent. Any azoospermic patient with an ejaculate volume < 1 mL should be tested for fructose levels, to identify seminal obstruction or atresia or ejaculatory tract obstruction.<sup>8</sup> Estimation of fructose levels is also helpful in identifying polyzoospermia and low motility. In cases with a very high sperm concentration (more than 350 million sperm/mL), the sperms are immotile due to a relative deficiency of fructose.<sup>8</sup>

European Society of Human Reproduction and Embryology (ESHRE) has questioned the reliability of the WHO (2010) reference values (5th centile provides the lower limit) in predicting fertility.<sup>10</sup>

## WHO 5 Manual (2010)—What is Objectionable?

- Lowered reference limits calculated from results on semen provided by recent fathers and men in a general population who are not sub-fertile.
- Data were collected over a long period of time, and external quality control had not been implemented.
- Data came from studies on semen samples obtained after 2–7 days of abstinence, and therefore reference values were not standardized.
- Ejaculate volume and sperm concentration, in particular, increase considerably with each day of increasing abstinence.<sup>10</sup>

## Recommendations From ESHRE

- Abstinence: Prescribed abstinence period of 3–4 days
- Sperm concentration: Simpler and less prone to error
- Sperm motility: Assessing four differential motility patterns of sperms allows distinction between rapid and slow progressive sperm, which is helpful in providing better prognostic information
- Sperm morphology: Maintaining the four-category assessment with calculation of TZI, improve the diagnostic and prognostic information
- Sperm vitality: Using correct criteria for live and dead spermatozoa<sup>10</sup>

Semen analysis is an essential part of infertility investigations, but has limited diagnostic value for infertility and prognostic value for ART.<sup>10</sup>

Routine semen parameters are the modest predictors of male fertility potential and have low prognostic value. They exhibit a high degree of variability, tell us about the function of testes, but fail to predict sperm chromatin quality and sperm function. The current WHO standards fail to meet rigorous clinical and statistical standards. Therefore, we need better markers of male fertility potential that will more accurately diagnose male infertility when compared to conventional semen parameters, and predict reproductive outcomes after ART.<sup>10</sup>

Abnormal semen analysis requires further evaluation to arrive at a diagnosis to provide direction to management (Table 5).<sup>10</sup>

**Table 5: Diagnostic evaluation methods of male infertility, apart from semen analysis<sup>10</sup>**

- ? Medical and sexual history
- ? Physical and genital examination
- ? Ultrasound—Scrotal and transrectal, doppler
- ? Endocrine evaluation—FSH, testosterone, PRL, E2
- ? Recommended in cases of:
  - ? Low sperm count especially if less than 10 million/mL
  - ? Impaired sexual function
  - ? Clinical findings suggestive of endocrinopathy
- ? Karyotyping
- ? Molecular genetics
  - ? Y-chromosome microdeletion
  - ? CBAVD and cystic fibrosis gene mutations
- ? Testicular biopsy diagnostic/therapeutic testicular
  - Should be done only when facilities are available for cryopreservation
- ? Post-ejaculatory urinalysis
- ? To differentiate between retrograde and anejaculation
  - ? Sperm function test if required

## Summary

- The properties of semen, such as liquefaction, viscosity, semen volume, and seminal pH, are evaluated during semen analysis.
- A sperm count of 48 million/mL is considered normal, whereas a sperm count below 13.5 million sperm/mL indicates male sub-fertility.
- Azoospermia may be defined as an extreme case of oligozoospermia, where sperm numbers are <1 million/mL.
- Sperm vitality is determined using the eosin-nigrosin test and the HOS test.
- Assessment of morphology is difficult, due to wide variations in sperm morphology.
- The secretions of acid phosphatase, citric acid, zinc, and magnesium are specific markers of the prostate gland. Fructose and prostaglandins are secreted by the seminal vesicles; and the epididymis secretes L-carnitine, alpha-glucosidase, and glycerophosphocholine.

## Importance of Sperm Function Testing in Diagnosis of Male Infertility

Sperm function tests have great importance in evaluating male infertility. These tests help in evaluating the functional aspects of the spermatozoon and can interpret the events that occur during the fertilization of the oocyte.<sup>8</sup>

Below are the advanced diagnostic andrology tests used in evaluating the sperm function (The Practice Committee of ASRM August 2012). Of these, the most commonly utilized are HOS and sperm DNA fragmentation test.<sup>3</sup>

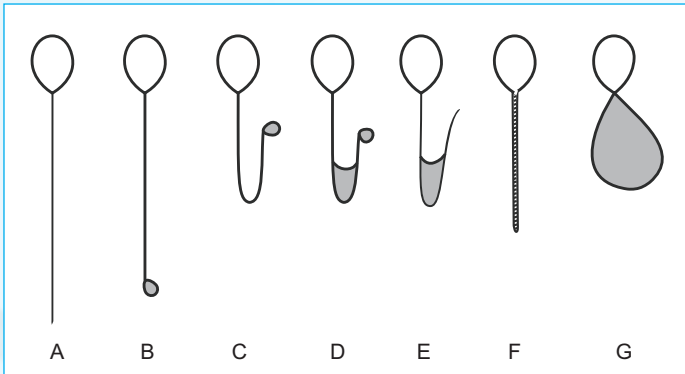
- PCT
- HOS
- Computer-assisted sperm analysis (CASA)
- ROS assessment
- Sperm DNA fragmentation
- Acrosome reaction
- Sperm penetration and zona binding
- Calcium influx<sup>3,8</sup>

## Post-coital test (PCT)

Post-coital test is a sperm mucus interaction test that identifies the penetration of sperm into the cervical mucus and can indicate defective sperm cells. It is not recommended these days, as it has no predictive value with respect to the pregnancy rate (Grade A). Post-coital test may be of value in the diagnosis of sexual dysfunction and ejaculatory problems. The results of PCT may have little effect on the treatment strategy, in the light of the widespread use of IUI for fertility problems. Moreover, the lack of effective treatment for anti-sperm antibodies may render PCT unnecessary.<sup>8</sup>

## Clinical Implications of Hypo-osmotic Swelling Test

As discussed in the previous section, the HOS test is based on the ability of live spermatozoa to withstand moderate hypo-osmotic stress. The clinical significance of the HOS test is being evaluated constantly in the literature. When subjected to hypo-osmotic stress, the membranes of spermatozoa swell and reach a steady state, i.e. fluid entering into the cells and being pumped out of the cells reaches a state of equilibrium. The extent of swelling of cells varies at this stage, but the cells do not burst open. These sperms are graded from A to G, based on the amount of swelling and curling of the tails.<sup>8</sup>



The total of each grade scored is reported as a percentage after counting 200 sperms. Sperms are considered normal if the percentage scored is more than 50% and abnormal if <50% of sperms show tail curling. An intermediate score is between 40% and 50%. Spermatozoan grades D, E, and F showed significantly lesser DNA fragmentation compared to grades A, B, and C when the HOS grading was correlated with DNA fragmentation status and terminal deoxynucleotidyl transferase-mediated dUTP nick-end labeling (TUNEL). This correlation is a reliable indicator for spermatozoon selection for intracytoplasmic sperm injection (ICSI).<sup>8</sup>

## Clinical Implications of Teratozoospermia Index

The teratozoospermia index (TZI) is an important sperm function test that is a good predictor of the fertilization and pregnancy rate. It is a multiple anomalies index, where a total of 100 sperms are counted; a record of the number of normal and abnormal sperms is also kept. Each abnormal sperm is evaluated for a maximum of 4 abnormalities. The TZI index is obtained by dividing the total number of all separate abnormalities by the total number of abnormal spermatozoa. The TZI is normal if <1.6; and if >1.8, ICSI is done irrespective of sperm count and motility.<sup>8</sup>

## Computer-Assisted Sperm Analysis: Advantages and Disadvantages

Computer-assisted sperm analysis (CASA) can analyze sperm motility or the kinematics of sperm motion, which cannot be evaluated by manual sperm analysis. The advantages of CASA are as follows:

- High-precision technique
- Provides quantitative assessment of sperm kinetics
- Provides data on sperm motility, straight-line and curvilinear velocity, linearity, average path velocity, amplitude of lateral head displacement, flagellar beat frequency, and hyperactivation<sup>12</sup>

Although CASA provides accurate data on sperm kinetics, it has a few disadvantages:

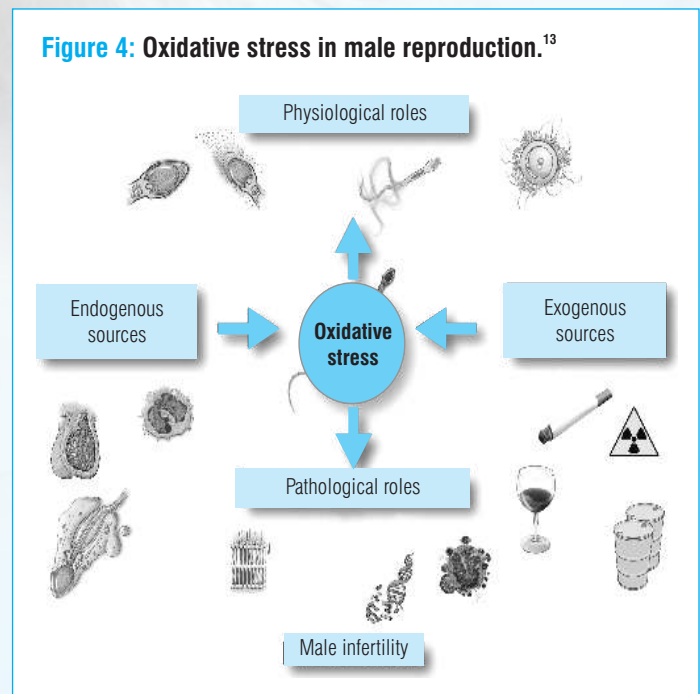
- When compared to CASA, manual assessment is much more accurate in distinguishing between debris, crystals, and immotile and dead sperm heads.
- Sperm concentration, sample preparation, and frame rate affect the accuracy of CASA.
- The stains used may affect the morphological determination.
- The equipment is expensive and requires a skilled technician for operation.<sup>11,12</sup>

Most studies suggest that CASA is not superior to conventional semen analysis (Grade A).

## Is Production of Reactive Oxygen Species a Cause of Concern? Good and Bad Sides

Production of reactive oxygen species (ROS) in excess is a concern due to its potential pathological effects. Oxygen is required for the metabolism of spermatozoa, but the metabolism of sperms produces harmful metabolites, such as ROS, that modify cell function, leading to their damage and destruction. Spermatozoa are naturally protected from such oxidants by the antioxidants present in the seminal vesicles. Oxidative stress is developed as a result of an imbalance between generating ROS and protective activities of antioxidants. Various factors contribute to the production of ROS and oxidative stress (Figure 4). Reactive oxygen species damage is more prominent in spermatozoa compared to other cells, as spermatozoa have relatively large quantities of polyunsaturated fatty acids and low concentration of scavenging enzymes.<sup>8</sup> Increased amounts of ROS cause oxidative stress, lipid peroxidation, and DNA damage.<sup>13</sup> Affected midpiece, acrosome or head of the sperm may result in compromised motility and gamete binding and may even lead to DNA damage. Thus, oxidative stress contributes to defective spermatogenesis and sperm function, leading to male factor infertility.<sup>13</sup>

Figure 4: Oxidative stress in male reproduction.<sup>13</sup>



Although higher concentrations of ROS are harmful, normal concentrations play an important role in physiological processes such as capacitation, hyperactivation, acrosome reaction, and sperm-oocyte fusion, for efficient fertilization.<sup>13</sup>

According to a study conducted by Aziz *et al.* among 39 infertile and 13 healthy fertile donors, a significant negative correlation was detected between sperm ROS production and the proportion of sperm with normal morphology and borderline morphology. A positive correlation was observed between the proportion of sperm with morphologically deformed sperms and leukocytes.<sup>8</sup>

## Laboratory Signs Suggesting Possible Sperm Oxidative Stress

1. Poor sperm motility
2. Teratozoospermia
3. High number of round cells (leukocytes) in semen-leukocytospermia is associated with increased ROS levels and can serve as an indirect measurement of ROS
4. Increased semen viscosity
5. Poor sperm membrane integrity on HOST
6. Poor fertilization on routine IVF
7. Poor sperm motility after overnight incubation with the oocyte
8. Poor blastocyst development in the absence of a clear female factor (advanced maternal age/poor ovarian reserve)<sup>8,13</sup>

## Measurement of Reactive Oxygen Species in Human Semen

Reactive oxygen species of sperm can be measured using cellular probes coupled with chemiluminescence detection in flow cytometry. This procedure is done by incubating a fresh semen sample or sperm suspensions by a redox-sensitive, light-emitting probe and by measuring the light emission over time with a light meter (luminometer).<sup>12</sup> Various direct and indirect assays available for the measurement of ROS are enumerated in the table below (Table 6).<sup>13</sup>

Direct assays	Indirect assays
Chemiluminescence assays	Myeloperoxidase test
Nitroblue tetrazolium test	Measurement of redox potential
Cytochrome c reduction	Lipid peroxidation levels
Flow cytometry	Chemokines
Electron spin resonance	Antioxidants

The normal range of ROS levels in washed sperm suspensions is 0.10 to 1.03×10<sup>6</sup> cpm per 20×10<sup>6</sup> sperm when measured by chemiluminescence.<sup>13</sup>

## Reactive Oxygen Species: Why is it not a Mainstream Investigation in the Evaluation of Male Infertility?

The measurement of ROS levels has not been included in the routine analysis of sub-fertile men, due to various reasons, including:

- Normal reference values not yet established
- Lack of a universally accepted analysis method
- Inconvenient and not cost-effective<sup>13</sup>

As the standardization of testing and the availability of these tests remain limited, it will be some time before this test becomes a part of regular evaluation for male subfertility.<sup>13</sup>

## Evaluation of Sperm DNA Fragmentation

Sperm chromatin consists of DNA+protamines. The DNA protamines in sperm chromatin lacks cytoplasm, due to which there is no transcription process or repair mechanism in the chromatin. Moreover, the high lipid content and presence of unsaturated fatty acids increases the susceptibility to damage (DNA, lipids). Sperm DNA damage is seen in the form of alteration in chromatin structure, DNA fragmentation, DNA oxidation, and protamine deficiency.<sup>6,12</sup>

Table 7 provides various mechanisms that causes DNA damage in spermatozoa.<sup>6,12</sup>

Advanced paternal age	
Genetic	<ul style="list-style-type: none"> <li>• Mutations</li> <li>• CABVD</li> <li>• Robertsonian translocations</li> <li>• Y chromosome deletion</li> </ul>
Lifestyle	<ul style="list-style-type: none"> <li>• Diet</li> <li>• Cigarette smoking</li> <li>• Alcohol</li> <li>• Recreational drugs</li> <li>• STIs</li> <li>• Injury</li> <li>• Infection</li> <li>• Obesity</li> <li>• Use of mobiles</li> </ul>
Occupation	<ul style="list-style-type: none"> <li>• Plastics and resins</li> <li>• Solvents</li> <li>• Wood processing</li> <li>• Metal industry</li> <li>• Automobile, truck, and aircraft mechanics</li> <li>• Sedentary or stressful jobs</li> <li>• Exposure to Wi-Fi</li> </ul>
Environmental	<ul style="list-style-type: none"> <li>• Endocrine disruptors</li> <li>• Xenoestrogens</li> <li>• Anti-androgens</li> <li>• Toxic compounds</li> <li>• Hormonal deficiency</li> <li>• Varicocele</li> <li>• Protamine deficiency</li> </ul>

## In the Testis

- Apoptosis during spermatogenesis
- DNA strand breaks during spermatogenesis

## Post-testicular

- DNA fragmentation via ROS

## Other Causes

- DNA fragmentation induced by endogenous caspases and endonuclease
- DNA damage induced by radio and chemotherapy
- DNA damage induced by environmental toxins

There are various tests that can be used to measure DNA damage.

### Direct Tests for DNA Damage:

- Terminal deoxynucleotidyl transferase-mediated deoxyuridine triphosphate (dUTP) nick end-labeling (TUNEL) assay
- Comet assay
- DNA oxidation measurement<sup>6,12</sup>

### Indirect Tests for DNA Damage:

- Sperm chromatin structure assay (SCSA)
- Sperm chromatin dispersion assay (SCD)
- Sperm fluorescence *in situ* hybridization analysis (FISH)<sup>12</sup>

The TUNEL and SCSA tests are used to detect histone-associated chromatin breaks, whereas the comet assay detects breaks in both protamine- and histone-bound chromatin. The SCD test is based on the principle that sperm with fragmented DNA fails to produce the characteristic halo of dispersed DNA loops that is observed in sperm with non-fragmented DNA following acid denaturation and removal of nuclear proteins. The sperm DNA fragmentation index (DFI) cut-off value varies from one assay to another, and is approximately 20% with TUNEL and 27%–30% with SCSA. These thresholds levels vary in native, unprocessed, and processed sperm prepared for ART by density centrifugation.<sup>6</sup>

## Evidence Linking Sperm DNA Fragmentation to Poor Reproductive Outcomes

The importance of good-quality sperm DNA with respect to reproductive outcomes has been studied in animal models, as evaluating it would be unethical in humans. A study was conducted by Fernandez-Gonzalez *et al.* using mouse spermatozoa with DNA damaged induced by cryo-injury. The study investigated the long-term consequences of using damaged parental DNA for the offspring. Pre-implantation embryo-development reduced the number of offspring per litter, and altered methylation of some epigenetically regulated genes was observed in the offspring. Also, anxiety, lack of habituation pattern, and defective spatial memory were seen. At 16 months, 33% of the female offspring had tumors in the lungs and dermis. During the first 5 months of life, 20% of the offspring died and 25% of the animals showed premature aging. The oocytes could partially repair fragmented DNA, leading to blastocyst formation and implantation,

producing live offspring. But the incomplete repair by oocytes led to long-term pathologies. Another study assessed the effects of sildenafil citrate in an animal model wherein males were treated with sildenafil. Although pups were born, there was both impaired fertilization and embryo development. The impairment of the embryo may be due to phosphodiesterase inhibitor effects on the embryo's DNA synthesis and repair. Pentoxifylline, a drug used to improve sperm motility, has also been associated with inhibition of DNA repair *in vitro* during the S and G2 phases in human ovarian cell lines. A recent human study conducted reported a negative correlation between sperm DNA oxidative damage after fertilization and blastocyst formation. Therefore, sperm DNA fragmentation has been associated with poor reproductive outcomes.<sup>14</sup>

High levels of sperm DNA damage have some correlation with oligospermia, poor motility and morphology, oligoasthenoteratozoospermia (OAT), cytoplasmic retention, and mitochondrial DNA damage. The DNA damage has impact on embryo/blastocyst development, progress of pregnancy, and pregnancy loss.<sup>14</sup>

The DNA damage can also have impact on health of the infant born:

- Dominant genetic mutations—Achondroplasia and Apert syndrome
- Neurological disorders—Schizophrenia, autism, and bipolar disorder
- Disease and birth defects—Neural tube defects, epilepsy, huntington disease, and Down's syndrome<sup>14</sup>

## Correlation Between Sperm DNA Damage and Pregnancy

A plethora of studies has been conducted to evaluate the relationship between sperm DNA damage and pregnancy. A systemic review, conducted by Zini *et al.* of 11 studies involving 1549 cycles of treatment (IVF or ICSI) with 640 pregnancies and 122 pregnancy losses, showed a statistically significant pregnancy loss associated with sperm DNA damage (combined odd ratio 2.48; 95% class interval, 1.52, 4.04;  $p < 0.0001$ ). An odds ratio of more than one indicates an increased chance of disease associated with DNA sperm integrity. The combined estimate from the 11 studies conclude that sperm DNA damage influences pregnancy loss after IVF and ICSI.<sup>15</sup>

## Indications for Sperm DNA Testing

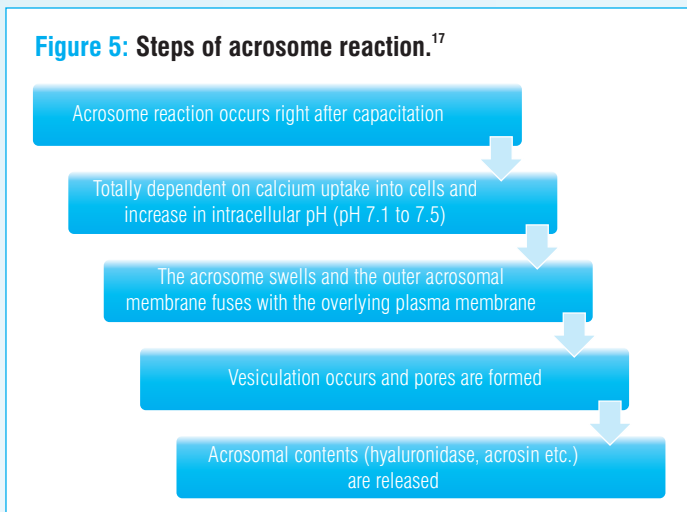
The test should be offered before IVF/ICSI to male partners of couples with a history of:<sup>16</sup>

1. Unexplained or persistent infertility	2. Recurrent miscarriage
3. Failure to conceive after 5–6 IUI cycles despite good count and motility	4. Prolonged stay in an environment that exposes to reproductive toxins
5. Low fertilization rates or poor embryo quality in IVF cycles	6. Abnormal semen analysis
7. Implantation failure after IVF	8. Advancing male age (>45 years)

## Acrosome Reaction

The spermatozoon binds to the zona pellucida, due to the acrosome reaction, which liberates hydrolytic enzymes due to exocytosis (Figure 5). Acrosomal reactivity can be assessed by microscopy, flow cytometry, and fluorescently labeled lecithins.<sup>17</sup>

**Figure 5: Steps of acrosome reaction.**<sup>17</sup>



- Detected using specialized staining techniques—Triple stain, trypan blue, fluorescent lectins and antibodies.
- Rates of spontaneous acrosome reactions and acrosome reactions induced by agents such as calcium ionophore and progesterone have been measured.
- Sperm from infertile men tend to demonstrate higher acrosome levels spontaneously, but lower levels in the presence of inducers.
- Labor-intensive and expensive.
- May be recommended in cases of profound abnormalities of head morphology or in unexplained infertility and repeated IVF failures.<sup>17</sup>

Spermatozoa cannot penetrate the oocyte without an acrosome. Spermatozoa with a large percentage of round head forms have difficulty penetrating the oocyte. The inducibility of the acrosome reaction and the penetration of sperm can be correlated; this correlation can provide useful information for the management and prediction of fertility. Acrosomal status is also useful in identifying abnormalities in sperm parameters. In asthenozoospermia, there is a reduced rate of induced acrosome reaction. In case of severe teratozoospermia, the calcium influx, as well as spontaneous and induced acrosome reactions, is defective. Also, the rate of ionophore-induced acrosome reaction is significantly related to fertilization rates in teratozoospermia patients. The acrosomal measure is also useful in making therapeutic decisions.<sup>18</sup>

### Clinical Implications of Acrosin Activity Test

Acrosin is serine protease-like enzyme that exhibits a lectin-like carbohydrate binding activity to the zona pellucida glycoproteins. Low acrosin activity has been associated with low sperm density, motility and with poor morphology.

### Biochemical Tests: Creatine Kinase

Creatine kinase is not involved directly in the fertilization process, but aids in the synthesis and utilization of the energy required by the sperm. Creatine kinase is an enzyme involved in energy production and utilization by the sperm cells via modulation of ATP production. It is a marker of sperm maturity, which correlates with the fertilizing capacity of the sperm. Elevated levels of CK are associated with an increased rate of functional

abnormalities and with increased cytoplasmic retention. Creatine kinase activity is observed to be lower in fertile oligospermic men than in infertile men. High creatine kinase levels denote a high residual cytoplasm and correlate inversely with the fertilizing potential of spermatozoa, indicating the degree of cellular immaturity. Creatine kinase levels can be a reliable marker for evaluating the quality of semen in men with unexplained infertility.<sup>19</sup>

Creatine kinase activity is analyzed by creatine kinase assay kits and is expressed in international units per  $10^8$  spermatozoa.<sup>19</sup>

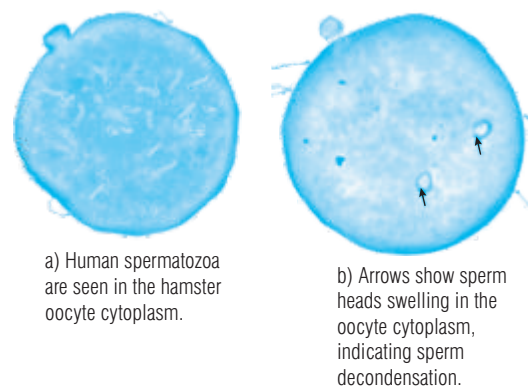
### Clinical Utility

The creatine kinase test is useful to investigate infertile male patients with varicocele, as high levels are frequently observed. It serves as a valuable guide for choosing between varicocele repair and assisted reproduction techniques.<sup>19</sup>

### Sperm Penetration and Sperm Binding Tests

The sperm penetration assay (SPA) evaluates the ability of spermatozoa to fertilize oocytes by testing capacitation, acrosome reaction, sperm/oolemma fusion, sperm incorporation into the ooplasm, and the decondensation of the sperm chromatin during the process.<sup>12</sup> This assay uses hamster eggs, and spermatozoa are exposed to hamster oocytes—which are devoid of zona pellucida (Figure 6). A study conducted by Vogiatzi *et al.* reported a higher sensitivity (52%–100%), specificity (0%–100%), positive predictive value (18%–100%) and negative predictive value (0%–100%), in terms of the diagnostic accuracy of SPA. The sensitivity of SPA is only 37%, with a specificity of 95%, which indicates that SPA is not reliable for selecting patients for treatment with IVF embryo transfer.<sup>17</sup>

**Figure 6: Illustration of sperm penetration assay.**



The penetration of spermatozoa into the zona pellucida is an important step leading to fertilization, which affects multiple sperm functions, such as capacitation and acrosome reaction. The two most common sperm-binding tests are the hemizona test (HZA) and the competitive intact zona sperm binding assay. The primary outcome of these tests is to evaluate the tight binding of sperm to the zona pellucida. In a study conducted by Oehninger *et al.*, it was reported that HZA can accurately predict the outcomes of IUI and IVF; therefore, the assay is of great use in the clinical diagnosis of infertility.<sup>17</sup>

## Does the Sperm Function Test Improve the Efficacy of Diagnosis and Treatment? Should it be Done in All Sub-fertility Cases?

Sperm function test should not be routine investigations as they are complex, expensive, not rigorously tested, do not always provide clinically useful information and typically do not affect treatment.<sup>18,19</sup>

The sperm function testing can assist the clinician in the decision-making process. Patients who have abnormal sperm functional test results can opt for ICSI instead of wasting time, effort, and expense on lower-complexity therapies, such as IUI.<sup>20</sup> The first step in evaluating male infertility is basic semen evaluation, which usually provides a diagnosis of male infertility without providing the etiological or pathophysiological cause. The need for sperm function tests arises when

- No specific therapy is indicated or the treatments have failed
- If the diagnosis is idiopathic infertility
- If the degree or abnormalities are severe.

Sperm function tests have a significant role in improving clinical management, as well as the efficacy of diagnosis and treatment.<sup>21</sup>

Selection of treatment modality for male sub-fertility depends on several factors. Three sperm function test which help in selecting the modality of treatment are TSI, HOS, and DFI.<sup>21</sup>

Parameter	IUI	IVF	ICSI
Concentration	>10 million/mL	1–10 million/mL	<1 million/mL
Total motile count	>5 million/mL	1–5 million/mL	<1 million/mL
24 hours sperm survival	>70%	<70%	<70%
TZI	<1.6	1.6–1.84	<1.84
HOS	>60%	50–60%	<50%
DFI	<15%	15–30%	>30% >60% TESA/ICSI

### Summary

- Conventional semen analysis does not provide precise information on the fertility potential of male subjects: normal semen analysis may not reflect defects in sperm function spontaneous pregnancy can still occur despite abnormal sperm parameters
- There is no agreement on the definition of normal semen parameters as they are being constantly revised in the light of the new study results
- The use of sperm function tests is recommended to refine the diagnosis, mainly when *in vitro* fertilization is indicated and no clear cause of the infertility has been found
- When subjected to hypo-osmotic stress, the membranes swell and reach a steady state, i.e. the fluid entering into the cells and pumped out of the cells reaches a state of equilibrium. The extent of swelling of cells varies at this stage, but the cells do not burst open.

- The TZI index is obtained by dividing the total number of separate abnormalities by the total number of abnormal spermatozoa.
- The TZI is normal if <1.6; and if >1.8, ICSI is done irrespective of sperm count and motility.
- The higher concentrations of ROS are harmful; normal concentrations play an important role in physiological processes such as capacitation, hyperactivation, acrosome reaction, and sperm-oocyte fusion, for efficient fertilization.
- The normal range of ROS levels in washed sperm suspensions is 0.10 to 1.03×10<sup>6</sup> cpm per 20×10<sup>6</sup> sperm when measured by chemiluminescence.
- Reactive oxygen species of sperm can be measured using cellular probes couples with flow cytometry by detection of chemiluminescence.
- The combined estimate from the 11 studies concluded that sperm DNA damage influences pregnancy loss after IVF and ICSI.
- Sperm DNA fragmentation may be suitable for couples with unexplained infertility or recurrent pregnancy loss or intrauterine insemination failure despite good sperm count and motility.
- The sensitivity of SPA is only 37%, with a specificity of 95%, which indicates that SPA is not reliable for selecting patients for treatment with IVF embryo transfer.
- The two most common sperm-binding tests are hemizona test (HZA) and the competitive intact zona sperm-binding assay.

### Extended Screening in Male Sub-fertility

When the initial screening evaluation reveals an abnormal male reproductive history or demonstrates abnormal semen parameters, a thorough evaluation by an andrologist is indicated. Apart from the sperm function test more detailed evaluation of the male partner is also important in couples with unexplained infertility and those who remain infertile after successful treatment of identified female infertility factors.

### Reproductive and Sexual History

The reproductive history should include coital frequency and timing, duration of infertility and prior fertility, childhood illnesses and developmental history, systemic medical illnesses (such as diabetes mellitus and upper respiratory diseases), previous surgery, medications and allergies, history of sexually transmitted infections, exposure to gonadal toxins (including environmental and chemical toxins and heat) and past or current use of anabolic steroids, recreational drugs, tobacco, and alcohol.

### Physical Examination and Ultrasound

Physical examination and ultrasound (scrotal and trans rectal ultrasound) is recommended in cases of abnormal male history, abnormal semen

analysis, unexplained infertility and treated female factor with persistent infertility. At the onset it is important to look for secondary sexual characteristics (body habitus, hair distribution, and breast development) followed by detailed examination of the penis (length, defects, and location of external urethral meatus) and testis (size and consistency), examination for the presence and consistency of vas and epididymis, evaluation of the pampiniformis plexus and a transrectal examination for accessory glands—seminal vesicles and prostate. Today, physical examination is enough for diagnosis of congenital bilateral aplasia of the vasa deferens (CBAVD), and scrotal exploration is unnecessary.

## Ultrasonography

Ultrasonography is a useful tool for detecting abnormalities of the male genital tract that may adversely affect fertility, but is usually indicated only in a small fraction of cases.<sup>22,23</sup>

**Transrectal ultrasonography** (TRUS) helps in detecting abnormalities of the seminal vesicle, prostate, and ejaculatory duct. Transrectal ultrasonography may be recommended in all oligospermic men having low volume ejaculates, palpable vasa, and normal testicular size with normal serum testosterone. One could diagnose complete or partial ejaculatory duct obstruction in the presence of dilated seminal vesicles or ejaculatory ducts and/or midline cystic prostatic structures.<sup>22,23</sup>

Men with ejaculatory duct obstruction usually produce a low-volume, acidic ejaculate containing no sperm or fructose. Men with CBAVD may exhibit similar findings because they often have absent or atrophic seminal vesicles. Men with partial ejaculatory duct obstruction exhibit low semen volume, oligo-asthenospermia, and poor progressive motility.<sup>22,23</sup>

## Scrotal Ultrasonography

Normally a careful physical examination by the clinician can identify most scrotal pathologies, including varicoceles, spermatoceles, absent vasa, epididymal induration, and testicular masses. Scrotal ultrasonography can identify occult varicoceles that are not palpable, but evidence has showed that such lesions have no clinical significance. Scrotal ultrasonography can be helpful for better defining vague or ambiguous physical examination findings or abnormalities (including apparent masses) and can be performed in men having testes located in the upper scrotum, a small scrotal sac, or other anatomy that hinders physical examination. Testicular ultrasonography is useful for men presenting with infertility and risk factors for testicular cancer, such as cryptorchidism or a previous testicular neoplasm.<sup>24</sup>

## Endocrine Evaluation

Endocrine evaluation identifies abnormalities of the hypothalamic-pituitary-testicular axis. It is indicated for men having abnormal semen parameters, particularly when the sperm concentration is below 10 million/mL, for impaired sexual function, and in the presence of other clinical findings that suggest a specific endocrinopathy.<sup>25</sup>

The minimum initial hormonal evaluation should include measurement of serum follicle-stimulating hormone (FSH) and total testosterone concentrations. When the total testosterone level is low (<300 ng/mL), a more extensive evaluation is indicated and should include a second measurement of total testosterone and measurements of serum-free

testosterone, luteinizing hormone (LH), prolactin, SHBG, and TSH. Most men with abnormal spermatogenesis have a normal serum FSH level; a markedly elevated serum FSH concentration clearly indicates an abnormality in spermatogenesis.<sup>25</sup>

Recently, the serum inhibin B levels and AMH concentration have emerged as markers of spermatogenesis. Inhibin B levels are significantly lower in infertile men than in fertile men and correlate better with sperm parameters than FSH levels.<sup>42</sup> Levels correlate with testicular cytology, but are not superior to FSH as predictors of the presence of sperm in TESE/FNA in men with azoospermia. It was also observed that stimulated levels of serum inhibin B and AMH levels do not add clinically relevant information in sub-fertile men compared to basal levels of these hormones.<sup>25</sup>

## Value of AMH Measurement in Infertile Men

- AMH a good candidate marker, as specifically secreted by Sertoli cells
- Correlated with spermatogenesis
- Serum AMH seems to be significantly lower among men with NOA than among OA and controls
- AMH is undetectable in seminal fluid for men with obstructive azoospermia
- In case of NOA, the seminal AMH predictive value on TESE outcome is not optimal in the identification of men with successful sperm retrieval.
- However, a wide overlapping of values between subjects prevents this hormone from being clinically useful.

## Post-ejaculatory Urinalysis

A low-volume or absent antegrade ejaculate suggests incomplete semen collection, retrograde ejaculation, lack of emission, ejaculatory duct obstruction, hypogonadism, or CBAVD. To exclude retrograde ejaculation, a post-ejaculatory urinalysis should be performed in men having an ejaculate volume less than 1.0 mL, except in those diagnosed with hypogonadism or CBAVD. Before advising examination of post-ejaculate urine, it is important to determine whether there was an improper or incomplete collection or a very short abstinence interval (less than 1 day) might be the cause.<sup>26</sup>

The post-ejaculatory urinalysis is performed by centrifuging the urine specimen for 10 minutes at 300 g, followed by microscopic examination of the pellet at 400 magnification. In men with azoospermia or aspermia, the presence of any sperm in the post-ejaculatory urinalysis suggests retrograde ejaculation. In men with low ejaculate volume and oligospermia, 'significant numbers' of sperm must be observed to support the diagnosis of retrograde ejaculation; there is no consensus of expert opinion on the minimum number of sperms required.<sup>26</sup>

## Genetic Screening

Normal sperm morphology is not always indicative of euploidy. Genetic abnormalities can cause infertility by affecting sperm production or sperm transport. The prevalence of chromosomal abnormalities is 10%–15% in



azoospermic men (approximately 5% in men with severe oligospermia (<5 million/mL), and less than 1% in men with normal sperm concentrations).<sup>27</sup>

Genetic screening includes karyotyping to rule out numerical chromosomal abnormalities such as Klinefelter's syndrome XXY and its variants, which account for about two-third of all chromosomal abnormalities observed in infertile men.<sup>28</sup> The prevalence of structural autosomal abnormalities, such as inversions and balanced translocations, is also higher in infertile men than in the general population.<sup>29</sup>

Moreover, those couples where the male partner has gross karyotypic abnormality are at an increased risk for miscarriages and for having children with chromosomal and congenital defects. Therefore, all men with non-obstructive azoospermia or severe oligospermia should be evaluated with a karyotype before using their sperm to perform ICSI.<sup>30</sup>

Molecular genetics (polymerase chain reaction techniques to analyze sequence tagged sites) is required to identify Y-chromosome micro-deletions that are associated with isolated defects in spermatogenesis and the abnormality of the cystic fibrosis trans-membrane conductance regulator (CFTR) gene in men with CBAVD. These test are important to identify genetic causes for infertility and have a major impact on the choice and outcome of treatment.<sup>30</sup>

Y-chromosome micro-deletions have been found in 7% of infertile men with severely impaired spermatogenesis and 16 % those with azoospermia, when compared to 2% of the normal men.<sup>47</sup> Therefore, it must be offered to those men who have non-obstructive azoospermia or severe oligospermia before performing ICSI with their sperm.<sup>30</sup>

Most deletions causing azoospermia or oligospermia occur in regions of the long arm of the Y chromosome (Yq11) known as the Azoospermia Factor (AZF) regions, designated as AZFa (proximal), AZFb (central), and AZFc (distal). AZFa, AZFb, and AZFc were established as the Y chromosome regions regulating spermatogenesis. Subsequent DNA sequencing approaches demonstrated that these regions harbor a total of 12 different genes/gene families necessary for spermatogenesis.<sup>31-33</sup>

For example, the DAZ (deleted in azoospermia) gene, which encodes a transcription factor usually present in men with normal fertility, is located in the AZFc region. The specific location of the deletion along the Y chromosome will influences the prognosis and help in deciding further treatment. The deletions involving the entire AZFa and AZFb region appear to predict a very poor prognosis for sperm retrieval.<sup>34,35</sup>

Men with micro-deletion in the AZFc region of the Y chromosome have severe oligospermia or azoospermic, but may still produce sufficient numbers of sperm to allow testicular sperm extraction.<sup>36</sup>

When ICSI is done with testicular sperm in men with AZFc micro-deletion of the Y chromosome, it is important to counsel the couple that the male progeny could inherit the abnormality and thus be infertile.<sup>37</sup>

Absence of Y-chromosome microdeletion does not rule out genetic abnormality because there may be other unknown, gene sequences on the Y chromosome that might also be required for normal spermatogenesis.<sup>37</sup>

There is a strong association between CBAVD and mutations of the cystic fibrosis gene mutations (CFTR) gene, which is located on chromosome 7.<sup>38</sup>

Almost all men with clinical cystic fibrosis exhibit CBAVD, and 80% of men with CBAVD have documented mutations of the CFTR gene. Failure to detect a CFTR abnormality in men with CBAVD does not exclude the presence of a mutation that cannot be identified with currently available methods. Therefore, men with CBAVD should be assumed to have a CFTR gene mutation. The risk of conceiving a child affected with CF is higher if the female partner is also a carrier.<sup>39,40</sup>

The prevalence of CFTR mutations also is increased among men with azoospermia related to congenital bilateral obstruction of the epididymides and in those with unilateral vasa agenesis. Consequently, genetic evaluation should be considered for those having either abnormality. Some men presenting with either unilateral or bilateral vasal agenesis or unilateral renal agenesis have mesonephric duct abnormalities associated with hereditary renal dysplasia (HRA), which has an autosomal dominant form of inheritance with incomplete penetrance and variable expression. These patients do not have CFTR mutations and require genetic counseling prior to IVF.<sup>39,40</sup>

## Sperm Chromosome Aneuploidy

Sperm DNA aneuploidy can be assessed by fluorescent *in situ* hybridization (FISH) technology.<sup>41</sup> Men with karyotypic abnormalities, severely abnormal sperm morphology, and non-obstructive azoospermia have the highest risk of sperm aneuploidy.<sup>41</sup> Men presenting with infertility and a normal karyotype had an increased frequency of meiotic alterations detectable in their sperm, and one study reported an incidence of 6%.<sup>42</sup>

Patients with recurrent pregnancy loss and recurrent IVF failure may also benefit from sperm aneuploidy testing.<sup>43,44</sup> But cost, inability to screen the actual sperm used in ICSI, and difficulty in assigning a meaningful risk assessment to couples based on the test results have limited the use of sperm aneuploidy testing in routine evaluation of the male partner.<sup>45</sup>

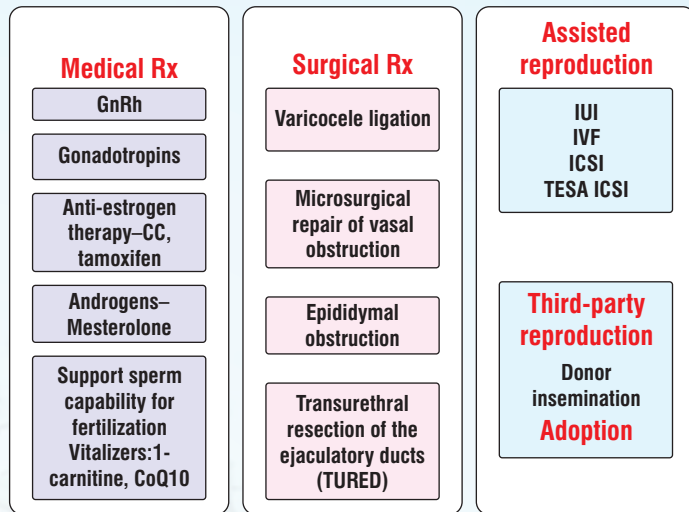
## Testicular Biopsy

When sperm retrieval for intracytoplasmic sperm injection (ICSI) is considered in azoospermic men, a testicular biopsy should be performed for prognostic purposes to determine whether spermatozoa are likely to be retrieved via testicular aspiration or extraction. The presence or absence of sperm in a biopsy specimen does not predict absolutely whether sperm are present elsewhere within that testicle. Today there is no consensus on which group of patients will benefit with testicular biopsy. The FSH and inhibin-B values do not serve as markers that can prognosticate the outcome of testicular biopsy.

A diagnostic testicular biopsy may be indicated in men having a normal serum FSH concentration with an average-sized or even smaller sized testis. This is because it has been observed that the incidence of obtaining sperms from the biopsy specimen is very low in the presence of high FSH and low inhibin B levels and when the testicular size is very small and the consistency is very soft. A unilateral or bilateral testicular biopsy can be done, although currently there is no clear consensus of opinion on the issue. If a unilateral biopsy is performed, it should be on the larger testis.<sup>46</sup>

## Management of Male Infertility

Treatment in male factor infertility is summarized in the table below.



### Medical Management

GnRH	<ul style="list-style-type: none"> <li>Indicated only in hypothalamic hypogonadism</li> <li>GnRh therapy with use of micropumps</li> <li>SC/IV administration with micropumps for several months makes compliance difficult</li> </ul>
Gonadotropin therapy	<ul style="list-style-type: none"> <li>Indicated only in hypothalamic hypogonadism with low FSH &amp; LH levels</li> <li>Dose: hCG - 2000 IU twice a week; FSH—75 IU thrice a week</li> <li>Given for 3 months</li> <li>First spermatozoa appear in the ejaculate after a median of 7 months.</li> </ul>
Anti-estrogen therapy—CC/tamoxifen	<ul style="list-style-type: none"> <li>Block the estrogen receptor, preventing inhibition of GT secretion</li> <li>Most controversial results—Some studies report benefit, while others do not</li> <li>CC—25 mg or tamoxifen 20 mg for 6 mts. Tamoxifen is preferred over CC, as it exerts a weaker estrogenic action.</li> <li>Establishment of clear cut guidelines for use necessary</li> </ul>
Aromatase inhibitors	<ul style="list-style-type: none"> <li>Anastrozole 1 mg daily, or letrozole 2.5 mg daily) increase testosterone, decrease estrogen levels, and inhibit the peripheral metabolism of testosterone</li> <li>Effective in restoring LH, FSH, and testosterone levels, improving semen parameters, and re-establishing fertility</li> </ul>
Androgens	<p>Note used these days</p> <ul style="list-style-type: none"> <li>Mesterolone: Suppresses tubular testicular function—Temporary oligo- or azoospermia, allowing function to rebound after treatment is stopped. No benefit reported,</li> <li>Testosterone undecanoate: To promote androgen bioactivity in epididymis and in accessory glands</li> <li>Amplification in bioavailability of DHT in peripheral blood</li> </ul>
Food and vitamin supplementation	<ul style="list-style-type: none"> <li>Carnitine, zinc, folic acid, astaxanthin, vitamin C, vitamin E, COQ may improve male infertility</li> <li>Direct effect on sertoli cells and epididymal function; improve spermatogenesis</li> <li>Involved in cellular respiration, improving motility, and preventing oxidative stress</li> </ul>
Other endocrinopathies and systemic diseases	<ul style="list-style-type: none"> <li>Thyroid, adrenal, hypothalamus and pituitary</li> <li>Diabetes, HT, renal disease, and malignancy</li> <li>Antibiotics for genital tract infection</li> <li>Cabergoline for hyperprolactinemia</li> </ul>

Moreover, it is important that the testicular biopsy should be done only where facilities are available for cryopreservation of the testicular sample in case sperms are obtained. These frozen sperms can then be used for ICSI without repeating the biopsy. Testicular biopsy also helps in differentiating obstructive from non-obstructive azoospermia. Thus testicular biopsy serves as a diagnostic as well as therapeutic procedure in this group of patients.<sup>46</sup>

A normal testicular biopsy implies obstruction at some level in the reproductive system, and the location must then be determined. Most men with obstructive azoospermia that cannot be attributed to iatrogenic vasal injury have bilateral epididymal obstruction, which can be confirmed by surgical exploration. Vasography may help to identify obstruction in the vas deferens or ejaculatory ducts. Due to the risk of vasal scarring and obstruction, vasography should not be performed at the time of diagnostic testicular biopsy, unless reconstructive surgery is performed at the same time.<sup>46</sup>

Testicular biopsy can be performed using a standard open incision technique called as testicular sperm extraction (TESE) or by percutaneous testicular sperm aspiration (TESA). Open testicular biopsy performed under local anesthesia and can be at a single site or multiple sites. It was introduced by Silber in 1995.<sup>46,47</sup> A single site has an advantage in that it avoids multiple testicular incisions and thus prevents injury to testicular arteries that are end-arteries. Injury at biopsy may result in partial testicular infarction if multiple incisions are taken.<sup>48</sup>

Testicular sperm aspiration or TEFNA (Testicular Fine Needle Aspiration) was introduced in 1995 by Bourne. In OA, it usually allows sperm retrieval sufficient for ICSI, but not for cryopreservation. However, in non-obstructive azoospermia (NOA), there may be no recovery of sperms. One of the complications of TESA is intratesticular hematoma, which has been reported in 7% of cases.<sup>49</sup>

The sperm recovery rate (SRR) in NOA is 51.3% with TESE and 21.1% with TESA. Testicular sperm aspiration is not indicated in NOA because of its low sperm retrieval rate, and it works only in cases of hypospermatogenesis.<sup>50</sup>

The overall SRR was 54% by mTESE and 10% by FNA, whereas the total complication rate following mTESE was 10% in the early phase and none in the long-term follow-up compared to 24% of FNA. Thus, mTESE is superior to FNA with respect to SRR and lower incidence of complications in NOA patients.<sup>51</sup>

In the histology of TESE samples from NOA, more than 50% of the men with germinal failure were found to have minute foci of spermatogenesis, which are insufficient to produce spermatozoa in the ejaculate. It is also observed that incomplete testicular failure may involve a sparse multi-focal distribution of spermatogenesis throughout the entire testicle.<sup>46,47</sup>

### Predictors of Sperm Recovery

- Histology of testicular biopsy gives information on the pattern of spermatogenesis and is predictive of the likelihood of finding sperm in the TESE procedure in 85% of patients.
- AZF 'Y' deletion site (AZFc SRR good)
- FSH not predictive (but may be helpful)
- Inhibin B—Some recent data doubt its value

## Treatment for Increased DFI

1. Vitamin (antioxidant) supplementation—Vitamins C, E, selenium, folate, zinc
2. Minimize exposure to gonadotoxins, hyperthermia (e.g., smoking, medication, saunas, hot tubs)
3. Antibiotics for semen infection
4. Varicocelectomy
5. ICSI with testicular sperm in patients with >70% sperm DNA damage

## Surgical Therapy

Varicocele ligation	<p>Varicocele associated with substantial risk of deteriorating testicular function but efficacy of varicocelectomy as a Rx controversial but beneficial in severe and symptomatic cases</p> <p>It can be done by the following options:</p> <ol style="list-style-type: none"> <li>1. Open via retroperitoneal, inguinal, or subinguinal approaches</li> <li>2. Microsurgically through an inguinal or subinguinal incision</li> <li>3. Laparoscopically using single-port, two-port, or three-port sites</li> <li>4. Robotically, employing either a transperitoneal approach or a subinguinal incision<sup>52</sup></li> </ol>
Treatment of obstructive azoospermia	<ul style="list-style-type: none"> <li>• Microsurgical repair of vasal obstruction—Patency rate of 80% and conception rate of 40%</li> <li>• Epididymal obstruction—Low success rate</li> <li>• Low volume ejaculate and severe oligozoospermia: Transurethral resection of the ejaculatory ducts (TURED)</li> </ul>

## Treatment of Azoospermia

### Azoospermia should be differentiated from aspermia and severe oligospermia

- Repeat SA after 4 weeks
- No sperms seen
  - ◆ Centrifugation for 15 mins (1500–1800 g)
  - ◆ Examine pellet under high-powered
  - ◆ Sperms detected in—35%
- Ejaculate volume < 1 mL:
  - ◆ Complete collection?
  - ◆ Check post-ejaculate urine sample

Azoospermia can be:

1. Obstructive azoospermia (OA)—15%–20%
  - Biologically: Normal functioning testis that produces sperm
  - Clinically: Good volume testis (> 15 mL) with dilated epididymis
  - Lab: FSH in the normal range

## Classification of obstructive azoospermia on the basis of the level of obstruction

Intratesticular obstruction (15% of OA)	Epididymal obstruction (30%–67% of OA)	Vas deferens obstruction
<ul style="list-style-type: none"> <li>• <b>Congenital forms</b> Dysjunction of rete testis-efferent ductules</li> <li>• <b>Acquired forms</b> Post-infective Post-traumatic</li> </ul>	<ul style="list-style-type: none"> <li>• <b>Congenital forms</b> Idiopathic epididymal obstruction</li> <li>• <b>Acquired forms</b> Post-infective Post-surgical</li> </ul>	<ul style="list-style-type: none"> <li>• <b>Congenital forms</b> Congenital absence of the vas deferens</li> <li>• <b>Acquired forms</b> Post-vasectomy Post-surgical (hernia, scrotal surgery)</li> </ul>
Ejaculatory duct obstruction (1%–3% of OA)	Functional obstruction of the distal seminal ductus	
<ul style="list-style-type: none"> <li>• <b>Congenital forms</b> Prostatic cysts (Müllerian cysts)</li> <li>• <b>Acquired forms</b> Post-surgical (bladder neck surgery) Post-infective</li> </ul>	<ul style="list-style-type: none"> <li>• <b>Acquired forms</b> Local neuropathy (diabetes, etc.)</li> </ul>	

2. Non-obstructive azoospermia (NOA)—80%–85%
  - Biologically: Dysfunctional testis with severe alteration of sperm production
  - Clinically: Hypotrophic (< 15 mL) and dystrophic testis
  - Lab: Elevated FSH

### Sperm Retrieval Techniques in OA

1. Intraoperative testicular sperm retrieval during Vasostomy/vasoepididymostomy
2. MESA (microsurgical epididymal sperm aspiration)
3. PESA (percutaneous epididymal sperm aspiration)
4. TESE (testicular sperm extraction)
5. TESA (testicular sperm aspiration)
6. TEFNA (testicular fine needle aspiration)

### Sperm Retrieval Techniques in NOA

1. TESA (testicular sperm aspiration)
2. TESE (testicular sperm extraction)—Multifocal
  - SRR in NOA = 51.3%
3. Micro-TESE (microdissection testicular sperm extraction)
  - Modifications of classic Micro-TESE
  - Snapshot: Retrieval in Klinefelter cases

Various clinical protocols are available for the selection of men, according to the classification of different forms of azoospermia. These protocols help in selecting men with various forms of azoospermia for treatment. Table 8 shows information on patient selection for treatment of azoospermia.<sup>55</sup>

**Table 8: Patient selection for treatment of azoospermia according to the clinical classification of azoospermia<sup>53</sup>**

Category of azoospermia	Clinical pointers as to the likely predisposing factors for azoospermia	Type of treatment
Obstructive azoospermia	Vasectomy, vasectomy reversal STD, swollen testis, distended epididymis, absence of vasa deferentia, absence of epididymis with semen pH <7, presence of sperm agglutinins	MESA, PESA, TESA
Azoospermia-ejaculatory duct dysfunction or retrograde ejaculation	Low semen volume (<1 mL), diabetes mellitus, retroperitoneal lymphadenectomy, bladder neck surgery, spinal injury	IUI or IVF with spermatozoa retrieved from TESA/alkalinized semen sample
Azoospermia due to hypogonadotropism	Kallmann's syndrome endocrine disorders, low FSH/LH	Gonadotropins or GnRH pump
Primary testicular sperm disorder	Idiopathic, chemotherapy, radiotherapy malignant disease, cryptorchidism orchidopexy, torsion of the testis mumps orchitis, abnormal karyotype testicular atrophy (≤12 mL) microdeletions of Y chromosome	TESE

## Summary

- Treatment options available for the management of male infertility are GnRH, gonadotropins, dopamine agonists, aromatase inhibitors, and SERMs.
- Varicocele repair involves ligation of the aberrantly dilated veins within the spermatic cord while preserving arterial and lymphatic supply and the deferential veins.
- Obstructive azoospermia is defined as the absence of spermatozoa and spermatogenic cells in semen and post-ejaculate urine due to obstruction.
- Scrotal imaging is an important tool for all scrotal abnormalities and testicular volume as measured by scrotal ultrasonography and is significantly correlated with testicular function.
- Serum AMH levels in men with non-obstructive azoospermia are significantly lower than those in men with obstructive azoospermia.
- Genetic factors that may play an important role in the evaluation and management of azoospermic male are pretesticular (Kallmann's syndrome), testicular (Klinefelter's syndrome or Y chromosome microdeletions) and post-testicular (congenital bilateral absence of the vas deferens).
- Gonadotropin treatment is available as self-administered subcutaneous injections with the dosage ranging between 75 and 150 IU of FSH or human menopausal gonadotropin, administered 2–3 times weekly along with 1500–2500 IU of hCG twice weekly.
- Follicle-stimulating hormone therapy is considered to be safe, well tolerated, and effective in men with non-obstructive azoospermia.

## Indications for Assisted Reproduction

### IUI

1. Mild-to-moderate oligospermia with >40% showing progressive motility
2. Antisperm antibody
3. Erectile dysfunction
4. Unexplained Infertility
5. Impossible vaginal ejaculation (psychogenic or organic impotence, severe hypospadias, retrograde ejaculation, and vaginal dysfunction)
6. Use of sperm cryopreserved prior to cancer treatment or vasectomy

### IVF

Results after IVF with male factor limited, as:

1. IVF requires adequate number of selected functional sperms and normal gamete interaction.
2. Gamete interaction may be deficient in patients with sperm disorder.

Failed fertilization with IVF is high in male factor infertility; thus ICSI is recommended.

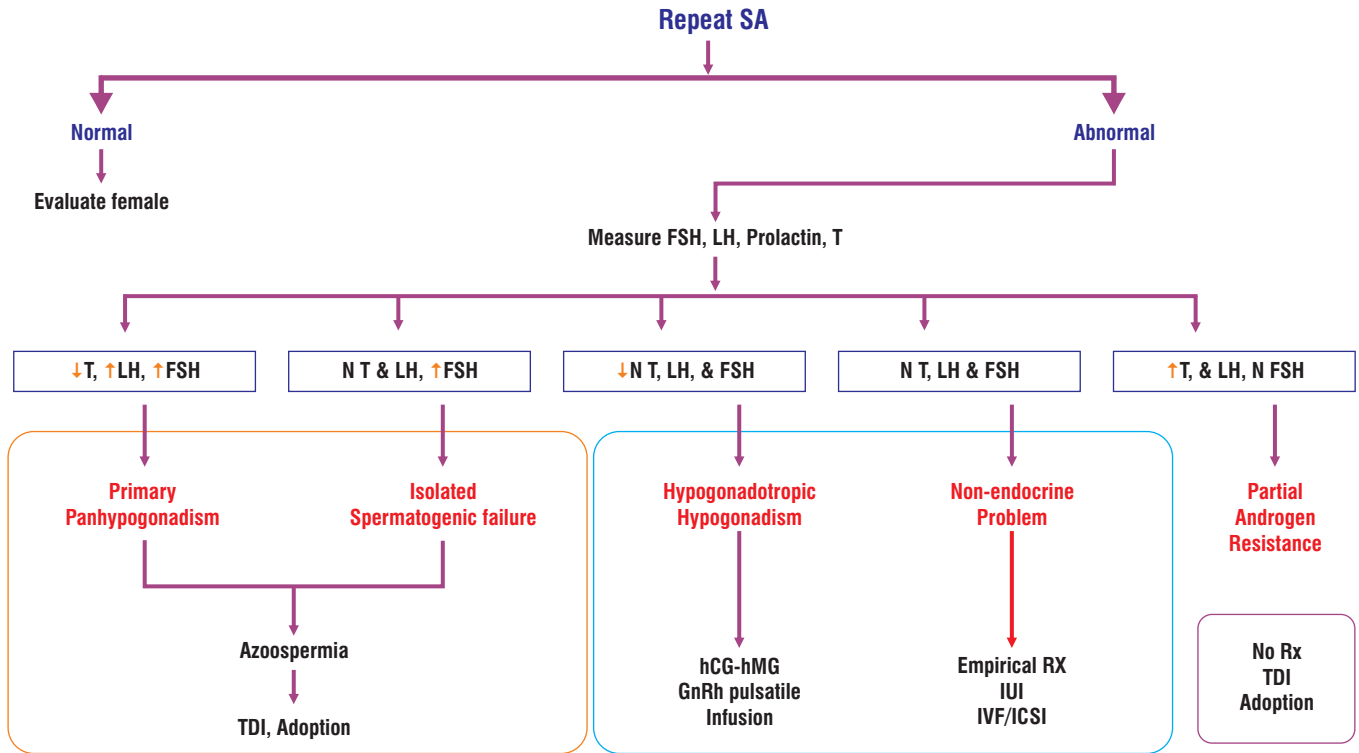
### ICSI

1. Treatment of choice for moderate-to-severe sperm dysfunction
2. Azoospermia:
  - i. MESA—ICSI
  - ii. PESA—ICSI
  - iii. TESA—ICSI
3. Failed fertilization at IVF
4. Antisperm antibody with failure to conceive with IUI & IVF
5. Defective acrosome reaction or capacitation
6. Abnormal sperm function

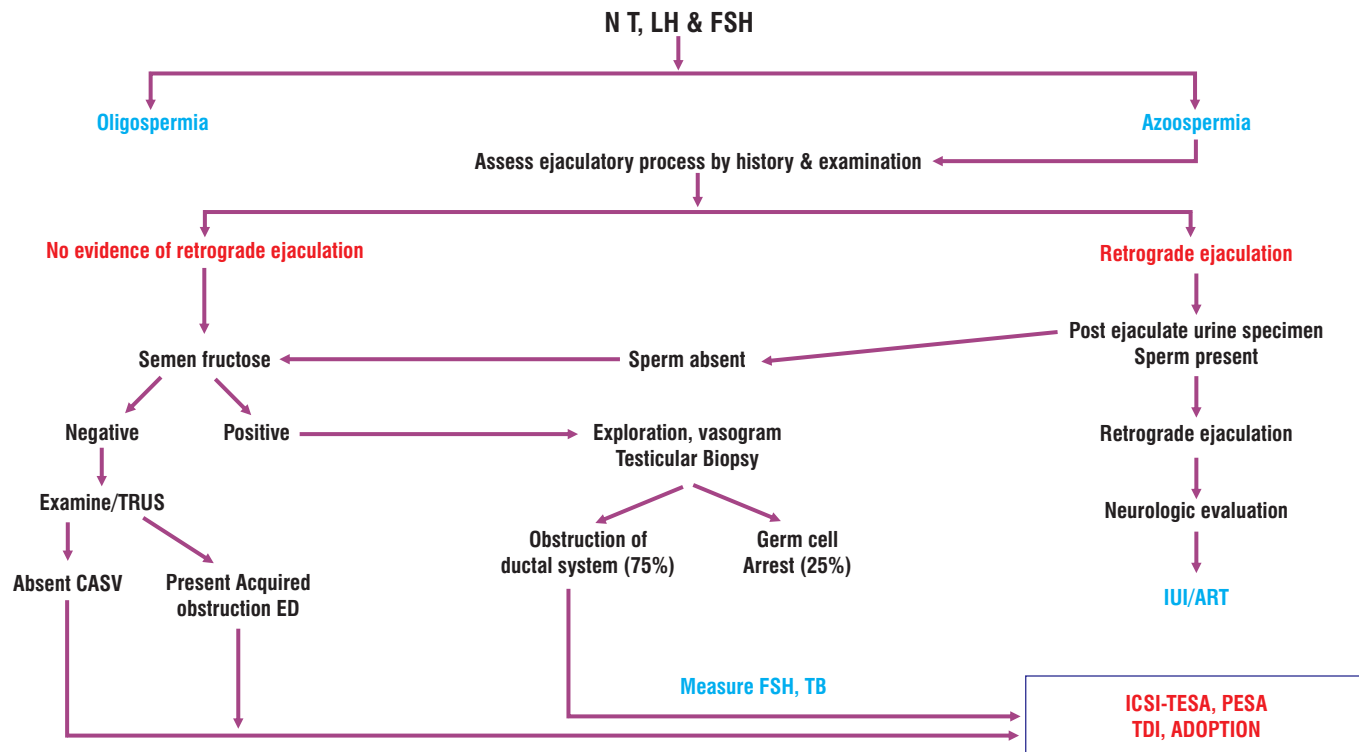
With ICSI, there is a risk of transferring the genetic (micro-deletions on long arm of Y Chromosome) cause of infertility to the next generation.

# Algorithms for Male Factor Evaluation

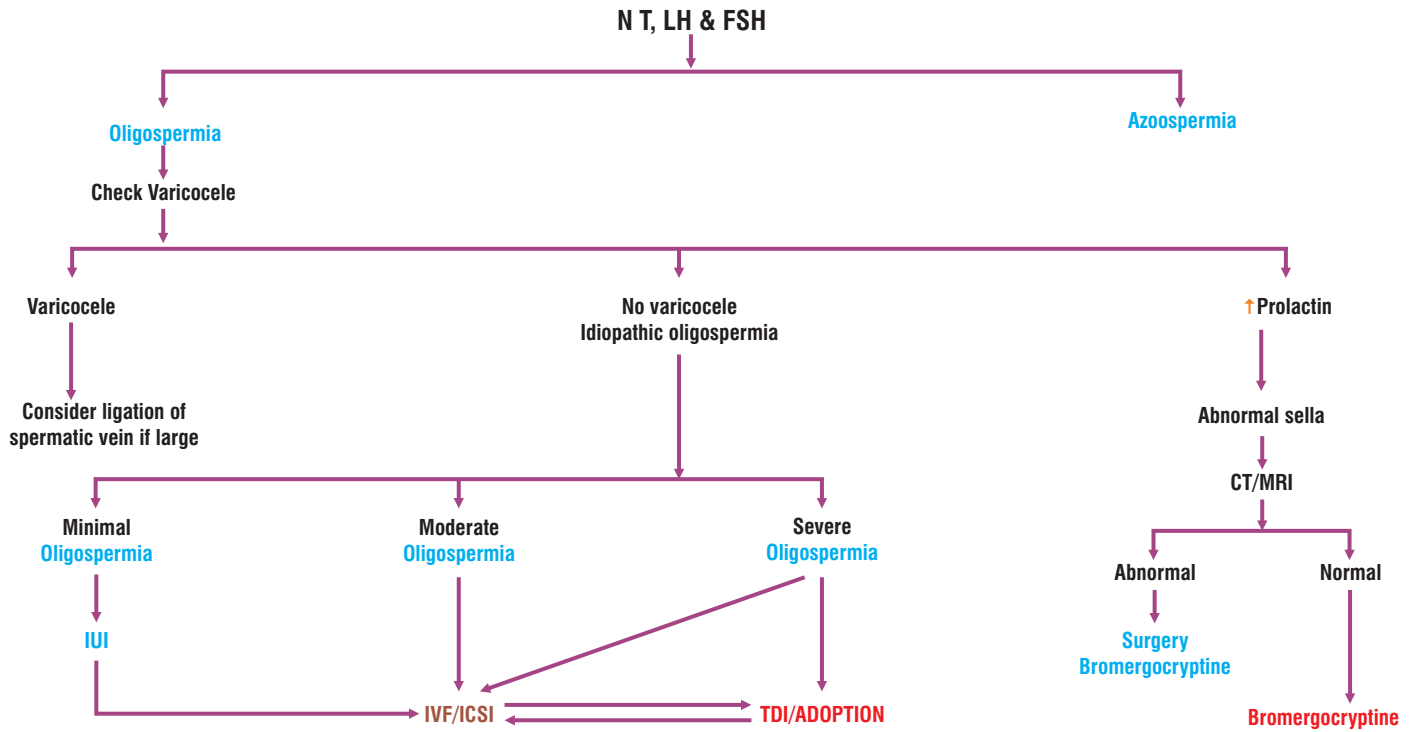
**Algorithm 1: Diagnostic and therapeutic algorithm for abnormal sperm parameters.**



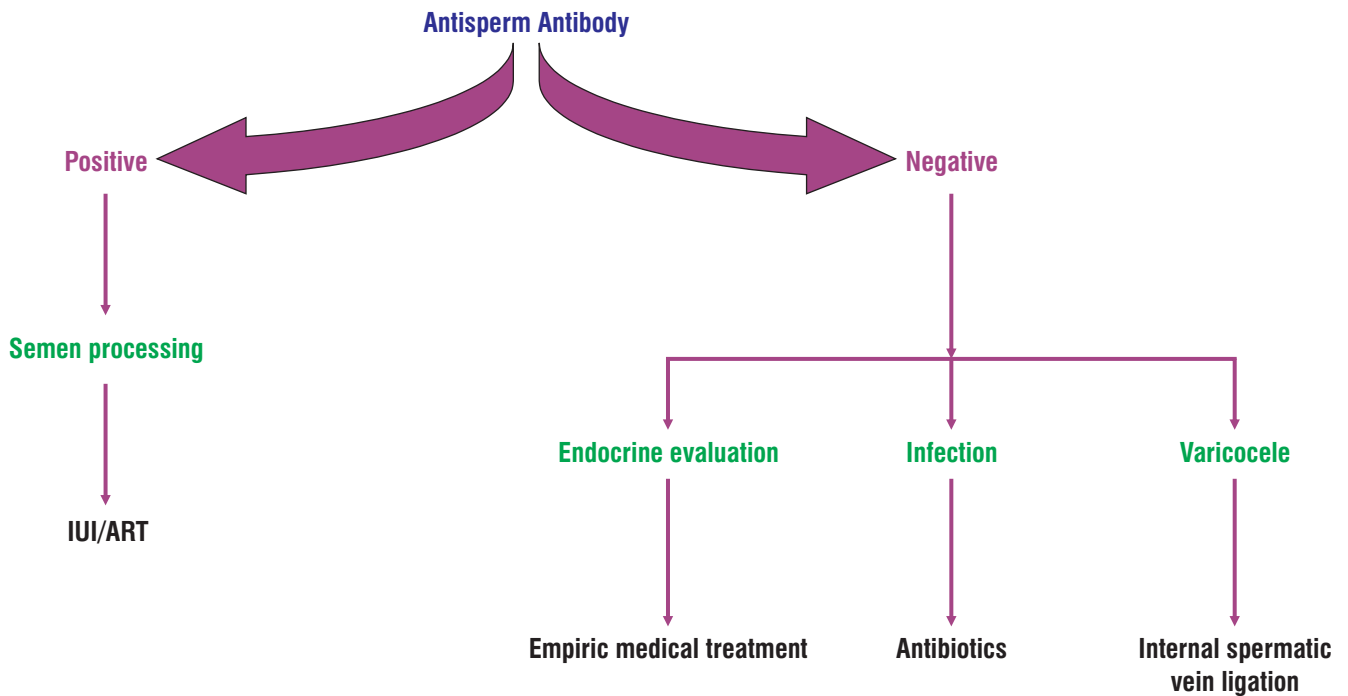
**Algorithm 2: Management of azoospermia with normal FSH, LH, and testosterone.**



**Algorithm 3: Oligospermia with increased abnormal forms.**



**Algorithm 4: Presence of agglutination, pus cells, and asthenospermia.**



## References

- Agarwal A, Mulgund A, Hamada A, *et al.* A unique view on male infertility around the globe. *Reprod Biol Endocrinol.* 2015;13:37.
- Kumar N, Singh AK. Trends of male factor infertility, an important cause of infertility: A review of literature. *J Hum Reprod Sci.* 2015;8(4):191–196.
- Diagnostic evaluation of the infertile male: A committee opinion. ASRM. *Fertil Steril.* 2012;98:294–301
- Jungwirth A, Diemer T, Dohle GR, *et al.* Guidelines on male infertility. European Association of Urology. 2015. Available at: [https://uroweb.org/wp-content/uploads/17-Male-Infertility\\_LR1.pdf](https://uroweb.org/wp-content/uploads/17-Male-Infertility_LR1.pdf). Accessed on: 4 April 2018.
- Barak S, Baker HWG. Clinical management of male infertility. 2016. Available at: <https://www.ncbi.nlm.nih.gov/books/NBK279160/>. Accessed on: 4 April 2018.
- Esteves SC, Hamada A, Kondray V, *et al.* What every gynecologist should know about male infertility: An update. *Arch Gynecol Obstet.* 2012;286:217–229.
- Jequier AM. Semen analysis: A new manual and its application to the understanding of semen and its pathology. *Asian J Androl.* 2010;12(1):11–13.
- Talwar P, Hayatnagar S. Sperm function test. *J Hum Reprod Sci.* 2015;8(2):61–69.
- Vasan SS. Semen analysis and sperm function tests: How much to test? *Indian Journal of Urology: IJU: Journal of the Urological Society of India.* 2011;27(1):41–48.
- Barratt CL, Björndahl L, Menkveld R, *et al.* ESHRE special interest group for andrology basic semen analysis course: A continued focus on accuracy, quality, efficiency and clinical relevance. *Hum Reprod.* 2011;26(12):3207–3212.
- Murray KS, James A, McGeady JB. The effect of the new 2010 World Health Organization criteria for semen analyses on male infertility. *Fertil Steril.* 2012;98(6):1428–31.
- Vasan SS. Semen analysis and sperm function tests: How much to test? *Indian J Urol.* 2011;27(1):41–48.
- Agarwal A, Virk G, Ong C, *et al.* Effect of oxidative stress on male reproduction. *World J Mens Health.* 2014;32(1):1–17.
- Lewis SEM, Kumar K. The paternal genome and the health of the assisted reproductive technology child. *Asian J Androl.* 2015;17:616–622.
- Zini A, Boman JM, Belzille E, *et al.* Sperm DNA damage is associated with an increased risk of pregnancy loss after IVF and ICSI: Systemic review and meta-analysis. *Hum Reprod.* 2008;23(12):2663–2668.
- Hsiao W. Sperm DNA fragmentation: Indication and uses. *Transl Androl Urol.* 2016;5:935–950.
- Kizilay F, Atlay B. Sperm function tests in clinical practice. *Turk J Urol.* 2017;43(4):393–400.
- Zeginiadou T, Papadimas J, Mantalenakis S. Acrosome reaction: Methods for detection and clinical significance. *Andrologia.* 2000;32:335–343.
- Sidhu RS, Sharma RK, Agarwal A. Relationship between creatine kinase activity and semen characteristics in subfertile men. *Int J Fertil.* 1998;43(4):192–197.
- Oehninger S, Franken DR, Ombelet W. Sperm functional tests. *Fertil Steril.* 2014;102:1528–1533.
- Oehninger S, Franken DR, Sayed E. Sperm function assays and their predictive value for fertilization outcome in IVF therapy: A meta-analysis. *Hum Reprod.* 2000;6(2):160–168.
- Carter SS, Shinohara K, Lipshultz LI. Transrectal ultrasonography in disorders of the seminal vesicles and ejaculatory ducts. *Urol Clin North Am.* 1989;16: 773–790.
- Jarow JP. Transrectal ultrasonography of infertile men. *Fertil Steril.* 1993;60: 1035–1039.
- Practice Committee of American Society for Reproductive M. The clinical utility of sperm DNA integrity testing. *Fertil Steril.* 2008;90:S178–80.
- Kumanov P, Nandipati K, Tomova A, *et al.* Inhibin B is a better marker of spermatogenesis than other hormones in the evaluation of male factor infertility. *Fertil Steril.* 2006;86:332–8.
- Van Assche E, Bonduelle M, Tournaye H, *et al.* Cytogenetics of infertile men. *Hum Reprod.* 1996;11(Suppl 4):1–25.
- Ravel C, Berthaut I, Bresson JL, Siffroi JP. Genetics Commission of the French Federation of C. Prevalence of chromosomal abnormalities in phenotypically normal and fertile adult males: Large-scale survey of over 10,000 sperm do- nor karyotypes. *Hum Reprod.* 2006;21:1484–1489.
- De Braekeleer M, Dao TN. Cytogenetic studies in male infertility: a review. *Hum Reprod.* 1991;6:245–50.
- Debiec-Rychter M, Jakubowski L, Truszczyk B, *et al.* Two familial 9;17 translocations with variable effect on male carriers fertility. *Fertil Steril.* 1992;57:933–5.
- Pryor JL, Kent-First M, Muallem A, *et al.* Microdeletions in the Y chromosome of infertile men. *N Engl J Med.* 1997;336:534–9.
- Kuroda-Kawaguchi T, Skaletsky H, Brown LG, *et al.* The AZFc region of the Y chromosome features massive palindromes and uniform recurrent deletions in infertile men. *Nat Genet.* 2001;29:279–286.
- Skaletsky H, Kuroda-Kawaguchi T, Minx PJ, *et al.* The male-specific region of the human Y chromosome is a mosaic of discrete sequence classes. *Nature.* 2003;423:825–837.
- Tilford CA, Kuroda-Kawaguchi T, Skaletsky H, *et al.* A physical map of the human Y chromosome. *Nature.* 2001;409:943–945.
- Brandell RA, Mielnik A, Liotta D, *et al.* AZFb deletions predict the absence of spermatozoa with testicular sperm extraction: preliminary report of a prognostic genetic test. *Hum Reprod.* 1998;13:2812–5.
- Krausz C, Quintana-Murci L, McElreavey K. Prognostic value of Y deletion analysis: what is the clinical prognostic value of Y chromosome microdeletion analysis? *Hum Reprod.* 2000;15:1431–4.
- Oates RD, Silber S, Brown LG, *et al.* Clinical characterization of 42 oligo-spermic or azoospermic men with microdeletion of the AZFc region of the Y chromosome, and of 18 children conceived via ICSI. *Hum Reprod.* 2002;17:2813–24.
- Kent-First MG, Kol S, Muallem A, *et al.* The incidence and possible relevance of Y-linked microdeletions in babies born after intracytoplasmic sperm injection and their infertile fathers. *Mol Hum Reprod.* 1996;2:943–50.
- Anguiano A, Oates RD, Amos JA, *et al.* Congenital bilateral absence of the vas deferens. A primarily genital form of cystic fibrosis. *JAMA.* 1992;267:1794–7.
- McCallum T, Milunsky J, Munarriz R, *et al.* Unilateral renal agenesis associated with congenital bilateral absence of the vas deferens: Phenotypic findings and genetic considerations. *Hum Reprod.* 2001;16:282–8.
- McPherson E, Carey J, Kramer A, *et al.* Dominantly inherited renal adysplasia. *Am J Med Genet.* 1987;26:863–72.
- Carrell DT. The clinical implementation of sperm chromosome aneuploidy testing: Pitfalls and promises. *J Androl.* 2008;29:124–33.
- Egozcue S, Blanco J, Vendrell JM, *et al.* Human male infertility: chromosome anomalies, meiotic disorders, abnormal spermatozoa and recurrent abortion. *Hum Reprod Update.* 2000;6:93–105.
- Carrell DT, Wilcox AL, Lowy L, *et al.* Elevated sperm chromosome aneuploidy and apoptosis in patients with un- explained recurrent pregnancy loss. *Obstet Gynecol.* 2003;101:1229–1235.
- Petit FM, Frydman N, Benkhalifa M, *et al.* Could sperm aneuploidy rate determination be used as a predictive test before intracytoplasmic sperm injection? *J Androl.* 2005;26:235–41.
- Tempest HG, Martin RH. Cytogenetic risks in chromosomally normal infertile men. *Curr Opin Obstet Gynecol.* 2009;21:223–7.
- Silber SJ, Van Steirteghem AC, Liu J, *et al.* High fertilization and pregnancy rate after Intracytoplasmic sperm injection with sperm obtained from testicle biopsy. *Hum Reprod.* 1995a;10: 148–152.
- Silber SJ, Nagy Z, Liu J, *et al.* The use of epididymal and testicular spermatozoa for intracytoplasmic sperm injection: the genetic implication for male infertility. *Hum Reprod.* 1995b;10: 2031–2043.
- Schlegel PN, Palermo GD, Goldstein M, *et al.* Testicular sperm extraction with intracytoplasmic sperm injection for non-obstructive azoospermia. *Urology.* 1997;49:435–440.
- Lewin A, Reubinoff B, Porat-Katz A, *et al.* Testicular fine needle aspiration: the alternative method for sperm retrieval in non-obstructive azoospermia. *Hum Reprod.* 1999;14:1785–1790.
- Dohle GR, Colpi GM, Hargreave TB, *et al.* The EAU Working Group on Male Infertility. EAU Guidelines on male infertility. *EurUrol.* 2005;48:703–711.
- El-Haggag S, Mostafa T, Abdel Nasser T, *et al.* Fine needle aspiration vs. mTESE in non-obstructive azoospermia. *Int J Androl.* 2007;27:32–36
- Evenson DP, Jost LK, Marshall D, *et al.* Utility of the sperm chromatin structure assay as a diagnostic and prognostic tool in the human fertility clinic. *Hum Reprod.* 1999;14:1039–1049.
- O'Connell MJ, *et al.* Never say never. The NIMA-related protein kinases in mitotic control. *Trends Cell Biol.* 2003;13(5):221–228.









You have reached the end of the module.  
To view the module online and complete the  
assessment test, scan this **QR code**.  
A certificate will be issued on completing all six modules.





**Disclaimer:** The matter published herein has been developed by clinicians and medical writers. It has also been validated by experts. Although great care has been taken in compiling and checking the information, the authors, BioQuest and its servants or agents, and sponsors shall not be responsible or in anyway, liable for any errors, omissions or inaccuracies in this publication whether arising from negligence or otherwise however, or for any consequences arising there from. The inclusion or exclusion of any product does not mean that the publisher advocates or rejects its use either generally or in any particular field or fields.